

Therapeutic Effects of *Lucilia sericata* Larvae on Cutaneous Leishmaniasis Wounds Caused by *Leishmania Major* using BALB/c Mice as Animal Model

Mohadese Kabiri, M.Sc.¹, Mohammad Saaid Dayer, Ph.D.², Fatemeh Ghaffarifar, Ph.D.³

1- MSc in Medical Entomology, Faculty of Medical Sciences, Tarbiat Modares University, Tehran, Iran

2- Assistant Professor of Medical Entomology, Faculty of Medical Sciences, Tarbiat Modares University, Tehran, Iran (Corresponding author; dayer@modares.ac.ir)

3- Professor of Parasitology, Faculty of Medical Sciences, Tarbiat Modares University, Tehran, Iran

Received: 12 July, 2017

Accepted: 26 December, 2017

ARTICLE INFO

Article type:

Original article

Keywords:

Cutaneous leishmaniasis

Lucilia sericata

Drug resistance

BALB/c Mice

Maggot therapy

Abstract

Background: Cutaneous Leishmaniasis (CL) is an endemic disease in Iran. The pentavalent antimonials as first-line drugs are losing efficacy because of side effects, disease relapse, and drug resistance. Application of *Lucilia sericata* larvae (maggot therapy) to diabetic and refractory wounds has been proven to be satisfactory for accelerating the healing process. In this study, therapeutic effects of *L. sericata* maggot were evaluated *in vivo* against leishmanial ulcer using BALB/c mice as animal model.

Methods: Female BALB/c mice were inoculated with promastigotes at the base of tails and kept for 28 days until the emergence of early ulcers. The mice then underwent 4 treatments as follows: Glucantime alone, Glucantime plus maggots, maggots alone, and positive control. The control and treated mice were monitored for a period of 5 weeks, during which the wound diameters were measured and recorded on a weekly basis. Data were analyzed using Kolmogorov-Smirnov test and ANOVA T-test.

Results: Statistical analysis showed significant difference ($P < 0.05$) between treated groups in terms of wound diameters. The Glucantime treated mice had the smallest-sized lesions. The wound sizes of otherwise treated mice were smaller than those of control mice, but with no statistically significant differences. Control mice harbored active and progressing ulcers, while treated mice had shrinking and healing wounds upon maggot therapy.

Conclusion: Maggot therapy accelerated the closure and healing process of leishmanial wounds in BALB/c mice and appeared promising as a new combinatorial therapeutics for leishmaniasis. However, further clinical trials are needed to evaluate the efficacy of maggot therapy modalities for leishmanial lesion care.

Copyright: 2017 The Author(s); Published by Kerman University of Medical Sciences. This is an open-access article distributed under the terms of the Creative Commons Attribution License (<http://creativecommons.org/licenses/by/4.0>), which permits unrestricted use, distribution, and reproduction in any medium, provided the original work is properly cited.

Citation: Kabiri M, Saaid Dayer M, Ghaffarifar F. Therapeutic Effects of *Lucilia sericata* Larvae on Cutaneous Leishmaniasis Wounds Caused by *Leishmania Major* using BALB/c Mice as Animal Model. Journal of Kerman University of Medical Sciences, 2017; 24(5): 389-396.

Introduction

The causative agent of leishmaniasis is a unicellular protozoan transmitted to human by bites of infected sand flies of the genus *Phlebotomus* in the Old World. The clinical

manifestations of the disease appear in one of three forms; cutaneous, mucocutaneous, and visceral leishmaniasis. Leishmaniasis is one of the widespread vector-borne parasitic diseases in tropical and sub-tropical parts of the world

including Iran. The World Health Organization has reported that leishmaniasis infects 12 million people worldwide, with about 2 million new cases each year in addition to exposing 350 million people to the risk of infection (1). The disease is endemic in 98 countries spread over the Old World (mainly North and East Africa, Middle East, Asia and southern Europe) and the New World (Central and South America) (2). The rise of new cases of cutaneous leishmaniasis in recent years has been attributed to growing migration from rural to urban areas, population displacement, increased exposure of sensitive individuals to the disease, environmental degradation, and ecological imbalance (3). Current anti-leishmanial chemotherapy mainly relies on pentavalent antimonials with serious limitations such as drug resistance, toxicity, lack of efficiency, and disease recurrence.

However, efforts are underway to achieve new anti-parasitic therapies of minimal side effects, which bring about faster wound healing without disfiguration (4). In spite of reports on maggot therapy application using free maggots of the facultative myiasis fly, *Lucilia sericata*, as a biosurgery in antiquity and in recent centuries, William Stevenson Baer successfully used the modern maggot debridement therapy (MDT) in the late 1920s for the treatment of acute bone infection or osteomyelitis (5). However, the treatment was abandoned in the mid-1940s due to the discovery of new drugs and modern antibiotics.

Nowadays, the failure of conventional treatments has encouraged the return to maggot therapy particularly for debridement of nonacute external wounds such as diabetic wounds and burns (6). The debridement takes place by maggots scraping necrotic devitalized tissues with mouth hooks and subtle body thorns (spicule) while secreting

proteolytic enzymes which render the dead tissues into a semi-fluid pus to be devoured (7, 8). In addition, by producing substances such as allantoin, calcium bicarbonate, and ammonia, maggots alkalize the wound pH, killing bacteria and accelerating wound healing. Peck and Kirkup showed that *Lucilia sericata* larvae could survive high doses of common antibacterials, antifungals, and anti-leishmanial drugs enabling biocompatibility to antimicrobials for various wound treatments (9). Also, active bacteria may be ingested and killed in the larvae gastrointestinal tract (10). This study aimed to investigate the therapeutic effects of free *Lucilia sericata* larvae on lesions caused by *Leishmania* parasites using BALB/c mice as an animal model.

Materials and Methods

Adult fly rearing

Lucilia flies were reared in cages of 50 x 50 x 50 cm dimensions using facilities of the Department of Medical Entomology insectarium at Tarbiat Modares University under controlled temperature of $22 \pm 3^\circ \text{C}$, $40 \pm 10\%$ relative humidity, and 12/12 hr light/dark cycle. To stimulate egg laying, fresh liver was supplied in disposable cups every 3 to 4 hours in the rearing cages. The used cups were then removed and placed in humid hatching (90% RH). After hatching, the larvae were fed with fresh meat until pre-pupation stage, when they were transferred to containers containing sawdust and kept in dark and dry place for pupation. Pupae were then transferred to rearing cages where emerged adults were fed with 5% sugar solution and mashed chicken liver. The adult flies were able to mate and lay eggs within 7 to 10 days upon being fed a carbohydrate and protein diet.

Preparation of sterile larvae

Using a sterile camel brush, the fly eggs were gently separated from egg laying medium and transferred into a sterile beaker containing sterile distilled water. The eggs were dispersed by agitation so that fertile eggs settled at the bottom of the beaker could be separated from unfertile floating ones. For disinfection, the fertile eggs were subjected to a 5 min washing in a 50 ml sterile Falcon containing diluted (0.5%) sodium hypochlorite followed by one-step washing with 70 % ethanol and 3 washing steps with sterile water. The eggs were then dried on sterile mesh under a sterile airflow cabinet. The dried disinfected eggs were then placed on blood agar plates. The inoculated plates were aseptically covered and placed at room temperature for 24 hours for egg hatching (11- 14).

Development and treatment of *Leishmania* lesions in mice

The standard strains of *Leishmania major* (MRHO / IR / 75 / ER) were obtained from Tarbiat Modares University stock cultures and used in this study. The strain was sub-cultured in liquid RPMI 1640 medium supplemented with 10% bovine serum and 1 to 1.5 percent streptomycin-penicillin solution. For *in vivo* experiments, 5- to 7-week-old Balb/c mice were purchased from Pasteur Institute of Karaj (Iran). Prior to experimentation, the mice were kept in favorable conditions at Animal House of Tarbiat Modares University. For lesion development in mice, 0.1 ml culture medium containing 2×10^6 promastigote at the stationary phase was subcutaneously injected in the bases of mice tails using fine insulin syringes. Almost 4 weeks after injection, small hard nodules appeared at the tail bases that soon developed into ulcers. To ensure the presence of *Leishmania*

parasite in the wound, smear samples were prepared and examined under microscope. The experiments were carried out on 20 BALB/c mice that had developed leishmanial ulcers. They were randomly divided into 4 groups (5 mice per each group), marked using picric acid dye and kept in separate cages. The test groups were as follows: (G1): positive control (promastigote infected mice), (G2): infected mice under treatment with meglumine (daily intramuscular injection of 20 mg/kg Glucantime), (G3): infected mice under treatment with maggots and meglumine (daily intramuscular injection of 20 mg/kg Glucantime) and (G4): infected mice under treatment with maggots. The treated mice were subjected to 5 times maggot therapy dressing at 3-day intervals each lasting for 48 hours followed by 24-hour wound aeration before another dressing started. Since the onset of treatments, using a digital caliper wound diameters of mice in all test groups were simultaneously measured once per week for 5 weeks post treatment, and the wound diameters were recorded.

Application of maggot therapy dressing on mice

Given the chewing behavior of mice and their strong refusal of any kind of dressing on their body, application of maggot therapy dressing, especially on their narrow dorsal areas where the ulcers developed, represented a serious challenge in this study. To overcome this challenge, small flat buttons were fixed around ulcers on mouse body by passing a tuft of hair through buttonholes and gluing them together. The fixed buttons served to anchor maggot therapy dressing (Fig. 1- B). Meanwhile, to prevent mice from accessing the dressing, Elizabethan collars were used around the mice necks to prevent dressing removal (Fig. 1-A).




Figure 1. Fixing maggot therapy dressing and Elizabethan collar on mice

Statistical analysis

Data were collected and recorded on SPSS worksheets. Analysis of data was performed using the Kolmogorov-Smirnov distribution test for single sample, ANOVA and T-test using SPSS version 16.0 for Windows. Differences were considered significant at $P < 0.05$.

Results

The results of Kolmogorov-Smirnov test indicated normal distributions for the variables of wound diameters measured at different time intervals at probability levels less than 0.5 ($P < 0.5$). Therefore, the statistical differences between treated groups (G2, G3, G4) were compared with control group (G1) using ANOVA test. Table 1 summarizes average sizes of lesions of various mouse groups and the result of ANOVA tests comparing mean sizes of lesions. Fig 2 shows the statistical difference of mean lesions of mouse groups treated

with different therapeutic treatments vis-à-vis the control group injected with promastigotes. Among the studied groups, only the G2 group showed significant reduction in the lesion sizes as compared with control and other treated groups. The average size of lesions in the control group grew bigger than those in the rest of treated groups, but differed only from those in the Glucantime-treated wounds. However, biologically, maggot therapy alone or together with Glucantime has effective debriding and disinfecting action on lesions, which enhances the healing process. In fact, the wounds treated with maggots alone or jointly with Glucantime showed apparent healing via developing granulated fresh tissues and stopping pus production and secondary inflammation (Fig 3- A). The untreated wounds in the control group were actively progressing with aggravated inflammation and more exudate (Fig 3- B).

Table 1. Results of ANOVA analyses of average lesion sizes (mm) of test groups

Test groups	Average wound diameters (mm)	Compared groups	Average difference	Sig	95% confidence intervals	
					Lower limit	Upper limit
G1 (Promastigote alone)	10.9	G2	5.748 *	0.004	2.153	9.342
		G3	0.882	0.610	-2.711	4.477
		G4	0.664	0.700	-2.929	4.259
G2 (Glucantime)	5.1	G1	-5.748 *	0.004	-9.342	-2.153
		G3	-4.865 *	0.011	-8.459	-1.270
		G4	-5.083 *	0.009	-8.672	-1.488
G3 (Glucantime+ maggots)	9.98	G1	-0.882	0.610	-4.477	2.711
		G2	4.865 *	0.011	1.270	8.459
		G4	-0.218	0.899	-3.812	3.376
G4 (Maggots only)	10.2	G1	-0.664	0.700	-4.259	2.929
		G2	5.083 *	0.009	1.488	8.672
		G3	0.218	0.899	-3.376	3.812

*Significant difference between average wound diameters at P<0.05)

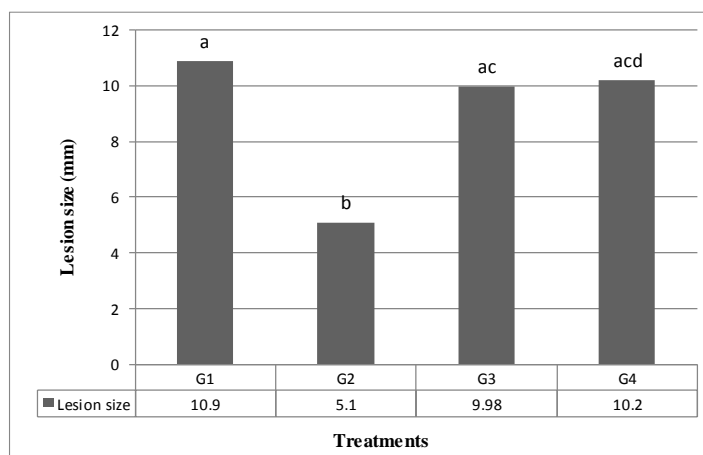


Fig 2. Lesion size on mice exposed to various therapeutic treatments compared with positive control

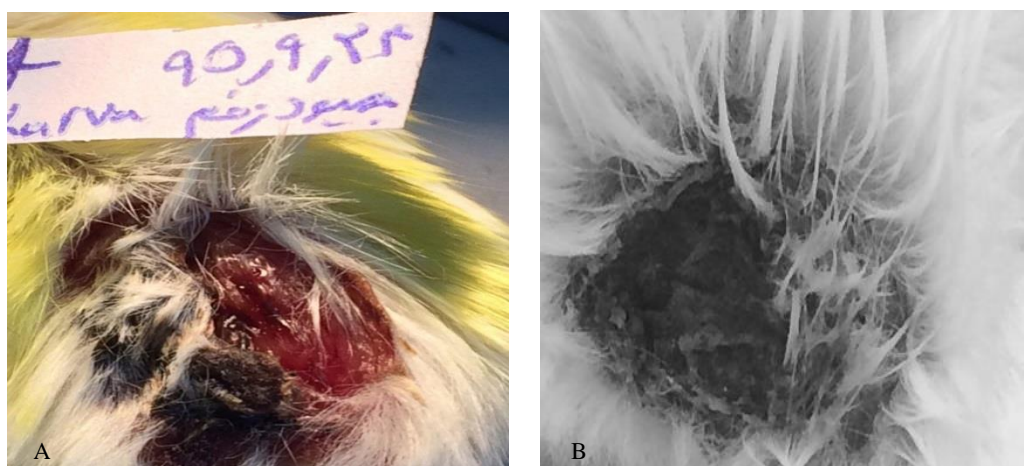


Fig 3. wound healing in treated group (A) and control group (B)

Discussion

Leishmaniasis is a disease transmitted by parasite-infected sand flies. The clinical manifestations of the disease include 3 forms of chronic skin ulcers, mucous membrane lesions, and severe internal organ complications. The cutaneous form is endemic in 98 countries throughout 5 continents (15, 16). A number of chemicals including miltefosine, paromomycin, amphotericin B, liposomal amphotericin B, allopurinol, and mepacrine are used to treat the disease (17). However, the first-line drugs for the treatment of leishmaniasis are antimony compounds, which reportedly come with side effects, drug resistance, and relapse. Leishmanial wounds are self-healing and cause no serious problem unless they occur in vital areas of the body. Nonetheless, patients may seek an effective and tolerable therapy because of long duration of lesions, likely secondary infections, and remaining disfiguring scars (18- 20).

Maggot therapy using *Lucilia* fly larvae has long been known as a medical practice for treatment of wounds and necrotic tissues among peoples of ancient cultures. Despite the old notion that wound debridement takes place by maggot physical activities including nibbling and movement, recent studies show that *L. sericata* maggots secrete proteolytic enzymes, which are able to solubilize necrotic tissues. The maggots' secretions were also shown to have antibacterial activity against Gram-positive and Gram-negative bacteria. In addition, maggots can consume bacteria as a part of their natural diet. Finally, maggots' movements stimulate wound healing process and formation of granulation tissue and assist human fibroblasts (21). Bexfield and coworkers (2010) identified 3 amino acid-like compounds including histidine, 3-guanidinopropionic acid, and valinol in maggot secretions of *Lucilia sericata* which stimulate the growth of endothelial

cells resulting in accelerated healing of refractory ulcers by increasing angiogenesis (22). However, Wollina and coworkers showed that maggot secretions exert positive effects on wound healing by accelerating development of granulation tissue and increasing tissue oxygenation (23). Recent research has shown that substances such as chymotrypsin, defensins and lucifencin II from secretion of *Lucilia sericata* larvae are highly effective on germs and biofilms of infectious wounds. Also, stimulated by microflora of chronic infectious ulcers, *Lucilia sericata* larvae may produce potentially active antibiotics which are effective for wound healing (24). Comparing the efficiency of application of *L. sericata* free-living larvae with their excretory substances on ulcers developed in the feet of BALB/c mice upon injection of leishmanial agent, Sanei-Dehkordi and coworkers claimed that average size of lesions in maggot treated mice were larger than in those treated with maggot secretions alone. They concluded that excretory substances were more efficient than larvae for wound healing (25).

In this study, the mean diameter of lesions in meglumine-treated mice showed significant difference with those recorded in otherwise treated mice ($p < 0.05$). Although, there was no meaningful difference between mean lesion sizes in mice treated with maggots alone or in combination with Glucantime with those in control group, the lesions in treated mice tended to grow granulation tissue and stop further expansion and inflammation. Therefore, maggot therapy may open a new horizon in the treatment of cutaneous leishmaniasis. Arrivillaga and coworkers revealed that free-living larvae of *L. sericata* can cure 80 to 100% of wounds caused by *Leishmania amazonensis* in *Mesocricetus aureatus* as an animal model (26). Polat and coworkers reported a

successful treatment of Glucantime-resistant wounds of cutaneous leishmaniasis (*L. major*) in some patients by applying *L. sericata* maggots over a short period of 10 days (27, 28). In their study, Choudhary and colleagues reported that maggot therapy of chronic wounds in small animals such as dogs and cats was associated with limb salvage saving them from amputation or euthanasia (29). In the present study, also, the clinical symptoms of treated mice were indicative of wound healing and thus successful treatment. However, the

results of this study can serve to encourage further applied research in this direction to produce enough scientific evidence on the effectiveness of maggot therapy using *Lucilia sericata* against cutaneous leishmaniasis.

Acknowledgment

The authors wish to acknowledge the technical and financial supports of Tarbiat Modares University in Tehran.

References

1. Kedzierski L, Sakthianandeswaren A, Curtis JM, Andrews PC, Junk PC, Kedzierska K. Leishmaniasis: current treatment and prospects for new drugs and vaccines. *Curr Med Chem* 2009; 16(5):599-614.
2. Desjeux P. Leishmaniasis. Public health aspects and control. *Clin Dermatol* 1996; 14(5):417-23.
3. Natera S, Machuca C, Padrón-Nieves M, Romero A, Díaz E, Ponte-Sucre A. Leishmania spp.: proficiency of drug-resistant parasites. *Int J Antimicrob Agents* 2007; 29(6):637-42.
4. Kobets T, Grekov I, Lipoldova M. Leishmaniasis: prevention, parasite detection and treatment *Curr Med Chem* 2012; 19(10):1443-74.
5. Sun X, Jiang K, Chen J, Wu L, Lu H, Wang A, Wang J. A systematic review of maggot debridement therapy for chronically infected wounds and ulcers. *Int J Infect Dis* 2014; 25:32-7.
6. Van der Plas MJ, van der Does AM, Baldry M, Dogterom-Ballering HC, van Gulpen C, van Dissel JT, et al. Maggot excretions/secretions inhibit multiple neutrophil pro-inflammatory responses. *Microbes Infect* 2007; 9(4):507-14.
7. Beasley WD, Hirst G. Making a meal of MRSA- the role of biosurgery in hospital-acquired infection. *J Hosp Infect* 2004; 56(1):6-9.
8. Robinson W, Norwood VH. The rôle of surgical maggots in the disinfection of osteomyelitis and other infected wounds. *The Journal of Bone & Joint Surgery* 1933; 15(2):409-12.
9. Peck GW, Kirkup BC. Biocompatibility of antimicrobials to maggot debridement therapy: medical maggots *Lucilia sericata* (Diptera: Calliphoridae) exhibit tolerance to clinical maximum doses of antimicrobials. *J Med Entomol* 2012; 49(5):1137-43.
10. Fleischmann W, Grassberger M, Sherman R. *Maggot Therapy: A Handbook of Maggot-Assisted Wound Healing*. USA: Thieme; 2004.
11. Wolff H, Hansson C. Rearing larvae of *Lucilia sericata* for chronic ulcer treatment--an improved method. *Acta Derm Venereol* 2005; 85(2):126-31.
12. Sherman RA, Hall MJ, Thomas S. Medicinal maggots: an ancient remedy for some contemporary afflictions. *Annu Rev Entomol* 2000; 45:55-81.
13. Pechter EA, Sherman RA. Maggot therapy: the surgical metamorphosis. *Plast Reconstr Surg* 1983; 72(4):567-70.
14. Kholoud A, Mohamed A, Azza MH. Parasitological, Bacteriological and Clinical Study of Wound Myiasis with a Trial of Maggot Therapy

- in Intractable Wounds. Egyptian Journal of Medical Microbiology 2009; 18(4):77-88.
15. Ben Salah A, Ben Messaoud N, Guedri E, Zaatour A, Ben Alaya N, Bettaieb J, et al. Topical paromomycin with or without gentamicin for cutaneous leishmaniasis. N Engl J Med 2013; 368(6):524-32.
 16. Makwali JA, Wanjala FM, Kaburi JC, Ingonga J, Byrum WW, Anjili CO. Combination and monotherapy of Leishmania major infection in BALB/c mice using plant extracts and herbicides. J Vector Borne Dis 2012; 49(3):123-30.
 17. Pearson RD, Sousa AQ. Clinical spectrum of Leishmaniasis. Clin Infect Dis 1996; 22(1):1-13.
 18. Croft SL, Seifert K, Yardley V. Current scenario of drug development for leishmaniasis. Indian J Med Res 2006; 123(3):399-410.
 19. Berman JD. Human leishmaniasis: clinical, diagnostic, and chemotherapeutic developments in the last 10 years. Clin Infect Dis 1997; 24(4):684-703.
 20. Brodskyn C, de Oliveira CI, Barral A, Barral-Netto M. Vaccines in leishmaniasis: advances in the last five years. Expert Rev Vaccines 2003; 2(5):705-17.
 21. Alnaimat SM, Wainwright M, Aladaileh SH. An initial in vitro investigation into the potential therapeutic use of *Lucilia sericata* maggot to control superficial fungal infections. Jordan Journal of Biological Sciences 2013; 6(2):137-42.
 22. Bexfield A, Bond AE, Morgan C, Wagstaff J, Newton RP, Ratcliffe NA, et al. Amino acid derivatives from *Lucilia sericata* excretions/secretions may contribute to the beneficial effects of maggot therapy via increased angiogenesis. Br J Dermatol 2010; 162(3):554-62.
 23. Wollina U, Liebold K, Schmidt WD, Hartmann M, Fassler D. Biosurgery supports granulation and debridement in chronic wounds--clinical data and remittance spectroscopy measurement. Int J Dermatol 2002;41(10):635-9.
 24. Wang XY, Li XR, Gao L, Wang JN. Could microbe stimulated maggots become a targeted natural antibiotics family? Med Hypotheses 2014; 83(1):60-1.
 25. Sanei-Dehkordi A, Khamesipour A, Akbarzadeh K, Akhavan AA, Mir Amin Mohammadi A, Mohammadi Y, et al. Anti Leishmania activity of *Lucilia sericata* and *Calliphora vicina* maggots in laboratory models. Exp Parasitol 2016; 170:59-65.
 26. Arrivillaga J, Rodríguez J, Oviedo M. Evaluación preliminar en un modelo animal de la terapia con larvas de *Lucilia sericata* para el tratamiento de la leishmaniasis cutánea. Biomédica 2008; 28(2):305-10.
 27. Polat E, Cakan H, Aslan M, Sirekbasan S, Kutlubay Z, Ipek T, et al. Detection of anti-leishmanial effect of the *Lucilia sericata* larval secretions in vitro and in vivo on *Leishmania tropica*: first work. Exp Parasitol 2012; 132(2):129-34.
 28. Polat E, Kutlubay Z. Meglumin antimoniat tedavisine dirençli dört kutanöz leishmaniosis olgusu. Türkiye Parazitoloj Dergisi 2014; 38:177-80.
 29. Choudhary V, Choudhary M, Pandey S, Chauhan VD, Hasnani JJ. Maggot debridement therapy as primary tool to treat chronic wound of animals. Vet World 2016; 9(4):403-9.