

## **A Rare Anatomical Variation in the Position of the Upper Trunk of the Brachial Plexus: A Case Report and Review of Literature**

Nowruz Najafzade <sup>1</sup>, Ramin Salimnejad <sup>1</sup>

1. Department of Anatomical Sciences and Pathology, School of Medicine, Ardabil University of Medical Sciences, Ardabil, Iran



### **ABSTRACT**

Anatomical variations of the brachial plexus may have not any clinical symptoms. One of these variations refers to the position of the roots and trunks of the brachial plexus. However, a good knowledge of this variation is very necessary in post-traumatic assessment, exploratory interventions, and administration of brachial plexus blocks in the interscalene space in order to surgical treatments. This report explains a case of variation in the position of the upper trunk of the brachial plexus which was observed in a male cadaver during routine dissection. Anatomically, the three trunks of the brachial plexus are originated from the C5-T1 spinal nerves, then, pass the interscalene space to enter the posterior triangle of the neck. It is not usual that the upper trunk of the brachial plexus pierces the anterior scalene muscle, but in this report, it was observed that the upper trunk of the brachial plexus piercing the anterior scalene muscle unilaterally, then, was divided into two divisions. To exploratory interventions of the neck for brachial plexus nerve repair and surgical therapies, a good knowledge of the roots and trunks of the brachial plexus position helps surgeons and anesthetists prevent possible mistakes during surgery and diagnose the upper limb paresthesias.

**Keywords:** Scalene muscle, Interscalene space, Brachial plexus, Dissection, Variations

**Citation:** Najafzade N, Salimnejad R. A Rare Anatomical Variation in the Position of the Upper Trunk of the Brachial Plexus: A Case Report and Review of Literature. *Journal of Kerman University of Medical Sciences*, 2021; 28(3): 297-300. doi: 10.22062/JKMU.2021.91670

**Received:** 09.07. 2020

**Accepted:** 23.10. 2020

**\*Correspondence:** Ramin Salimnejad; Email: R.salimnegad67@gmail.com

**Published by Kerman University of Medical Sciences**

## Introduction

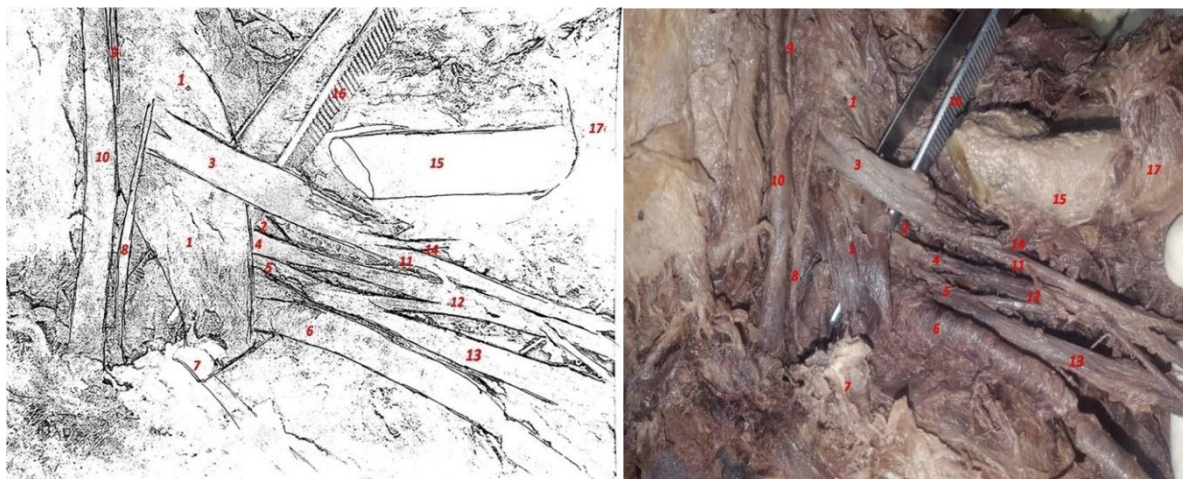
The human brachial plexus develops from the differentiation of mesenchymal stem cells during the 4th week in utero (1,2). The brachial plexus is formed by the union of the ventral rami of spinal nerves (sometimes there is also a branch of C4 or T2) and provides sensory and motor innervations to the upper limb and part of the back (3). This plexus extends from the posterior triangle of the neck to the armpit and includes several parts: Roots, trunks (upper, middle, and lower), divisions, cords (medial, lateral, and posterior), and terminal branches. Three trunks of the brachial plexus are formed by the union of the roots. In this way, the ventral rami of C5-C6 unite to form the upper trunk, C7 alone forms middle trunk and C8-T1 unite to form the lower trunk (4). Anatomically, the trunks of the brachial plexus pass through the space between the anterior and middle scalene muscles (interscalene space), and eventually, were divided into the anterior and posterior divisions (3,4). The contributions from C4 (pre-fixed) and T2 (post-fixed) roots are the most frequent variations of brachial plexus. Since several studies have reported different variations in the brachial plexus, but there are few reports regarding the variations in the position of the upper trunk of the brachial plexus (3,5,6).

The knowledge about that is important for anatomists, radiologists, surgeons, and

anesthetists. These findings can help to correctly detect traumatic and non-traumatic injuries in surgical operations of the brachial plexus and brachial plexus block (7). The aim of this study was to report a rare variation in the position of the upper trunk of the brachial plexus.

## Case Report

The posterior triangles of the neck on both sides of a male cadaver aged 40-45 years were carefully dissected in the dissecting room of Ardabil University of Medical Sciences. During routine anatomical dissection, the trunks of brachial plexus were traced proximally to the anterior and middle scalene muscles. An unusual unilateral variation was found in the position of the upper trunk of the left brachial plexus. Generally, the roots and trunks of the brachial plexus pass through the space between the anterior and middle scalene muscles. In this case, it was observed that the upper trunk of the brachial plexus was embedded in the substance of the anterior scalene muscle (close to the anterior surface) instead of locating in the interscalene space. In this study, the upper trunk, after piercing the anterior scalene muscle substance, traversed a few centimeters, and finally, was divided into two divisions. The terminal branches were generally involved in the formation of the brachial plexus (Figure 1).



**Figure 1.** Schematic image of the left side of the neck and axillary region. 1: Anterior scalene muscle, 2: Middle scalene muscle, 3: Upper trunk, 4: Middle trunk, 5: Lower trunk, 6: Subclavian artery, 7: First rib, 8: Phrenic nerve, 9: Vagus nerve, 10: Common carotid artery, 11: Lateral cord, 12: Posterior cord, 13: Medial cord, 14: Lateral pectoral nerve, 15: Clavicle, 16: Forceps, 17: Pectoralis minor. Variation is seen in the relation between the anterior scalene muscle and the upper trunk of the brachial plexus.

## Discussion

Cadaveric studies of brachial plexus can help anatomists, radiologists, surgeons, and anesthetists to have an adequate prognosis regarding the formation of neural plexus and the relations of nerves with respect to scalene muscles (8). The scalene muscles are anatomically important structures in the neck (6). Phrenic nerve is located in front of the anterior scalene muscle, and the roots of the brachial plexus and the subclavian artery pass behind it. The middle scalene is another important muscle that is located posterior to the brachial plexus and the subclavian artery (4). Both of these muscles superiorly originate from the transverse processes of the cervical vertebrae and attach to the upper surface of the first rib. There is a triangular interval between the anterior and middle scalene muscles which provides a passage for the roots and the trunks of the brachial plexus and the subclavian artery (interscalene space or scalene hiatus) (4). Interscalene space is clinically important because any pressure on the structures passing through this space causes the development of thoracic outlet syndrome (TOS) (9,10). Also, this space is used in the local brachial plexus block (interscalene block) for shoulder and upper arm surgery, which was first described by Winnie (11).

Few studies have demonstrated the relationship between the roots and trunks of the brachial plexus against scalene muscles (9,12). Knowledge of these relationships can be clinically important because passing parts of the brachial plexus inside the scalene muscles can be compressed in a scissor-like fashion upon contraction and cause chronic pain syndromes of the neck (10). It has also been observed in some cases that localized anesthesia in the interscalene space (supraclavicular brachial plexus block) does not produce a good result in the anesthetizing roots of the brachial plexus (13). In these studies, anesthesiologists have observed that the anesthetic drug in the supraclavicular

block of the brachial plexus more spread on the inferior than on the upper, which can be due to the passage of brachial plexus from the muscle substance, may undergo scissor-like compression from muscular contraction and prevents the drug from spreading upwards (14).

The present study showed that the upper trunk of the brachial plexus can be embedded in the substance of the anterior scalene muscle instead of locating in the interscalene space. Some previous studies have shown that the roots and trunks of the brachial plexus can pass through the anterior scalene muscle (9,15). Overall, the findings are consistent with this report and demonstrate variations in the position of the roots and trunks of the brachial plexus. Similar to the present study, Yogesh et al. (2013) have reported that the roots of brachial plexus were present in the scalene hiatus in the 3 of 24 cadavers (15). In another study, Harry et al. (1997) reported that in 15% of sides, the C5 and C6 roots together pierced the substance of the anterior scalene muscle (8% bilaterally) (9).

Embryologically, axon pathfinding is controlled by chemical pathways, and deviations from this pathway may lead to variations in neural networks (16). Furthermore, it has been described that developmental anomalies for axonal guidance in the neural plexus can lead to a rare situation in which the roots and trunks of the brachial plexus do not pass through the interscalene space (17). Therefore, understanding these variations can help diagnose and treat patients.

## Conclusion

To repair and resection of brachial plexus injuries, a good knowledge of the roots and trunks of the brachial plexus variations helps surgeons and anesthetists to prevent possible mistakes during surgery.

## Conflict of interest

The authors declare that there is no conflict of interest.

## References

1. Lewis WH. The development of the arm in man. *American Journal of Anatomy* 1902; 1(2):145-83.
2. Shinohara H, Naora H, Hashimoto R, Hatta T, Tanaka O. Development of the innervation pattern in the upper limb of staged human embryos. *ActaAnat (Basel)* 1990; 138(3):265-9.
3. TayefiNasrabadi H, Abedelahi A, Shoorei H, Shokoohi M, Salimnejad R, Dolatkah MA, et al. A variation of Musculocutaneous nerve without piercing the coracobrachialis muscle while communicating to the median nerve: a case report and literature review. *International Journal of Surgery Case Reports* 2017; 41:453-5.
4. Standring S. *Gray's Anatomy: The Anatomical Basis of Clinical Practice*. 41st ed. Elsevier; 2015.
5. Fazan VP, de Souza Amadeu A, Caleffi AL, Rodrigues Filho OA. Brachial plexus variations in its formation and main branches. *ActaCirurgicaBrasileira* 2003; 18(Suppl 5):14-8.
6. Rajanigandha V, Ranade AV, Pai MM, Rai R, Prabhu LV, Nayak SR. The scalenus accessorius muscle. *International Journal of Morphology* 2008; 26(2):385-8.
7. Gregory J, Cowey A, Jones M, Pickard S, Ford D. The anatomy, investigations and management of adult brachial plexus injuries. *Orthopaedics and Trauma* 2009; 23(6):420-32.
8. Terzis JK, Kostopoulos VK. The surgical treatment of brachial plexus injuries in adults. *PlastReconstrSurg* 2007; 119(4):73e-92.
9. Harry WG, Bennett JD, Guha SC. Scalene muscles and the brachial plexus: anatomical variations and their clinical significance. *ClinAnat* 1997; 10(4):250-2.
10. Savgaonkar MG, Chimmalgi M, Kulkarni UK. Anatomy of inter-scalene triangle and its role in thoracic outlet compression syndrome. *J AnatSoc India* 2006; 55(2):7-12.
11. Winnie AP. Interscalene brachial plexus block. *AnesthAnalg* 1970; 49(3):455-66.
12. Johnson EO, Vekris M, Demesticha T, Soucacos PN. Neuroanatomy of the brachial plexus: normal and variant anatomy of its formation. *SurgRadiolAnat* 2010; 32(3):291-7.
13. Neal JM, Hebl JR, Gerancher J, Hogan QH. Brachial plexus anesthesia: essentials of our current understanding. *RegAnesth Pain Med* 2002; 27(4):402-28.
14. Bakker D. Costo-clavicular compression: a review. *Pain in Shoulder and Arm* 1979; 1:185-200.
15. Yogesh M, Viveka S, Sudha MJ, Santhosh Kumar SC, Revankar S. Relation of roots and trunks of brachial plexus to scalenus anterior muscle and its clinical significance. *IOSR Journal of Dental and Medical Sciences* 2013; 11(4):3-5.
16. Bonanomi D, Pfaff SL. Motor axon pathfinding. *Cold Spring Harb Perspect Biol* 2010; 2(3):a001735.
17. Martinoli C, Gandolfo N, Perez MM, Klauser A, Palmieri F, Padua L, et al., editors. Brachial plexus and nerves about the shoulder. *SeminMusculoskeletRadiol* 2010; 14(5):523-46.