



# Can a Platelet Flag Prevent Misdiagnosis? A Report of Two Different Platelet Counts by Two Different Cell Counters for a Patient

Mohammad Ghorbani<sup>1,2</sup>, Babak Mahmoudi<sup>3</sup>, Zahra Khoshnegah<sup>4</sup>, Amin Solouki<sup>5</sup>, Mohammad Reza Javan<sup>6</sup>,  
Abuzar Zakeri<sup>7</sup>, Hamid Reza Niazkar<sup>8</sup>, Amir Mohammad Solouki<sup>9</sup>

<sup>1</sup>Laboratory Hematology and Transfusion Medicine, Department of Medical Laboratory Sciences, Faculty of Allied Medicine, Gonabad University of Medical Sciences, Gonabad, Iran

<sup>2</sup>Laboratory Hematology and Transfusion Medicine, Department of Pathology, Faculty of Medicine, Gonabad University of Medical Sciences, Gonabad, Iran

<sup>3</sup>Allameh Bohlool Hospital, Gonabad University of Medical Sciences, Gonabad, Iran

<sup>4</sup>Department of Hematology and Blood Banking, Faculty of Medicine, Gonabad University of Medical Sciences, Gonabad, Iran

<sup>5</sup>Department of Hematology and Blood Banking, School of Allied Medical Sciences, Shahid Beheshti University of Medical Sciences, Tehran, Iran

<sup>6</sup>Department of Anatomy, Physiology and Pharmacology, College of Medicine, University of Saskatchewan, Saskatoon, SK, Canada

<sup>7</sup>Hematology Department, Allameh Bohlool Hospital, Gonabad University of Medical Sciences, Gonabad, Iran

<sup>8</sup>Student Research Committee, Gonabad University of Medical Sciences, Gonabad, Iran

<sup>9</sup>Internal Medicine Department, School of Medicine, Birjand University of Medical Sciences, Birjand, Iran

\*Corresponding Author: Amir Mohammad Solouki, Email: [solouki.amir.m@gmail.com](mailto:solouki.amir.m@gmail.com)

## Abstract

**Background:** As platelet count is one of the valuable laboratory tests for disease diagnosis, its errors, such as the upper discrimination for the platelet volume distribution (PU) flag, could cause problems and misdiagnosis. Blood cell histogram evaluation can come close to overcoming the limitations of the platelet counting test.

**Case Report:** In this study, a 36-year-old thalassemia minor male presented with the symptoms of fever and myalgia. Petechiae and purpura were observed in the patient's lower extremities in the physical examination. Nihon Kohden Celltac G and Sysmex XP-300 cell counters were used to report the platelet count, which was reported to be 10 000/ $\mu$ L and 129 000/ $\mu$ L, respectively. However, the peripheral blood smear (PBS) assessment confirmed that the result of the Sysmex XP-300 cell counter was wrong, and a platelet flag was seen. This situation can be corrected by the complete blood count (CBC) histogram and PBS evaluation.

**Discussion:** Sysmex XP-300 cell counter's inability to differentiate severely microcytic cells from platelets can cause the PU error, which means the severe microcytic red blood cells (RBCs) were counted as platelets, causing the platelet count to be reported higher than the actual number for this patient. The PU flag means the platelet histogram intersects the PU line without touching the zero baselines, which occur in conditions such as platelet clumps, giant platelets, microcytic, and fragmented or dysplastic RBCs. In the Nihon Kohden Celltac G cell counter, this error was prevented due to the change in the PU line, and the patient's actual platelet count was reported. To avoid such errors, abnormal platelet counts should always be confirmed with the findings of PBS.

**Conclusion:** Poikilocytosis, such as microcytic RBCs and, can cause the PU flag, so platelet and erythrocyte histograms and PBS evaluation should be assessed.

**Keywords:** Sysmex XP-300, Nihon Kohden Celltac G cell counter, Platelet count, Platelet flag, CBC histogram

**Citation:** Ghorbani M, Mahmoudi B, Khoshnegah Z, Solouki A, Javan MR, Zakeri A, Niazkar HR, Solouki AM. Can a platelet flag prevent misdiagnosis? a report of two different platelet counts by two different cell counters for a patient. *Journal of Kerman University of Medical Sciences*. 2024;31(1):51–54. doi: [10.34172/jkmu.2024.09](https://doi.org/10.34172/jkmu.2024.09)

**Received:** July 10, 2023, **Accepted:** October 12, 2023, **ePublished:** February 29, 2024

## Introduction

The evaluation of platelet count is a common hematology assessment in everyday clinical practice. Numerous diagnostic and therapeutic decisions are made based on

the platelet count. Also, the platelet count is a prognostic factor associated with various diseases (1). Therefore, inaccurate assessments of platelet count will inevitably lead to clinical misdiagnosis and mismanagement.



Furthermore, wrong platelet count may happen due to various technical issues such as inappropriate sampling, the nature of the patient's sample such as the presence of cold platelet antibodies, the platelet satellite phenomenon, and abnormal cell volume (2).

Nowadays, platelet counting is performed by automated cell counter instruments, which count and differentiate cells based on cell impedance or light scattering. In the instrument, platelets and red blood cells (RBCs) are counted in one chamber and are separated from each other according to differences in size and volume. Thus, automated cell counter instruments cannot differentiate platelets from other similarly sized particles, such as small or fragmented RBCs and immune complexes. As a result, the platelet count of a thrombocytopenic patient may be incorrectly reported in the normal range. This error presents upper discrimination for the platelet volume distribution (PU) flag (3).

In addition, the assessment of blood cell histograms may provide information on many hematological conditions. In this regard, histograms are derived by plotting the volume of each cell on the X-axis and their relative number on the Y-axis. Furthermore, they may help diagnose early-stage hematologic diseases (4,5). However, complete blood count (CBC) histogram analysis may be neglected by clinicians. In the current study, one of the platelet histogram errors in a patient with a history of thalassemia minor is presented by comparing Sysmex XP-300 and Nihon Kohden Celltac G cell counter results.

### Case Report

A 36-year-old male was referred to the hospital complaining of fever and myalgia. He was previously diagnosed with thalassemia minor. Examination revealed petechiae and purpura in the lower extremities. Laboratory assessments showed a significant decrease in mean corpuscular volume (MCV) and increased RBC count. Initially, the platelet count was reported to be approximately 10000/ $\mu$ L in the sample with ethylenediaminetetraacetic acid (EDTA) anticoagulant analyzed by Nihon Kohden Celltac G instrument, which was consistent with the patient's clinical signs. However, later, the platelets were reported to be 129000/ $\mu$ L.

Further investigations revealed that Sysmex XP-300 (an automated 3-part differential hematology cell counter) had reported the later platelet count (129000/ $\mu$ L). The platelet count was assessed by examining a peripheral blood smear (PBS), which indicated severe thrombocytopenia, microcytic hypochromic anemia, and target cells (Table 1). In addition, platelet aggregation and platelet satellitism were not seen. The platelet histogram distribution curve is shown in Figure 1, which indicates a significant number of cells larger than normal volume and a PU error. It should be noted that the results of the patient's coagulation tests, including prothrombin

time (PT), partial thromboplastin time (PTT), and international normalized ratio (INR), were normal.

### Discussion

The current case report presented a 36-year-old male with a history of thalassemia minor with severe thrombocytopenia (approximately 10000/ $\mu$ L) in Nihon Kohden Celltac G cell counter. However, in the Sysmex XP-300 cell counter results, the platelet count was indicated to be 129000/ $\mu$ L, which was in contrast with the PBS findings. This difference was due to Sysmex XP-300 cell counter's inability to differentiate between severely microcytic RBCs and platelets, and these microcytic RBCs were counted as platelets, falsely raising the reported platelet counts in this patient. However, in the Nihon Kohden Celltac G cell counter, this error was prevented due to the change in the PU line (the boundary between RBC and platelet counts), and the actual platelet count of the patient was reported. Sysmex XP-300 is a 3-part automatic cell counter manufactured by Sysmex.

On the other hand, Nihon Kohden Celltac G is a fully automatic hematology analyzer. Both instruments are widely used throughout Iran and the world, although Sysmex products are more common in Iran. It should be noted that in cell counter instruments, platelets and RBCs are counted in the same chamber (6).

The PU flag occurs when the platelet histogram intersects the PU line and does not reach the zero baselines (Figure 2) (7). This error arises in platelet clumps (EDTA incompatibility and clotted sample), giant platelets, or microcytic, fragmented, or dysplastic RBCs in hemolytic anemia. Although platelet volume is between 2 to 25 femtoliters (fL), the PU point varies between 12 to 30 fL to prevent miscounting platelets as RBCs in the presence of giant platelets or miscounting microcytic or fragmented RBCs as platelets to get an accurate platelet count (8). Due to severely microcytic RBCs (MCV=63

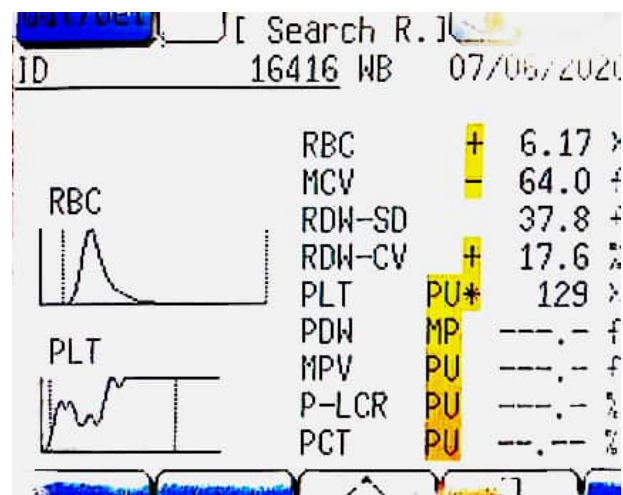


Figure 1. Platelet histogram with PU error (red arrow) leads to a false increase in platelet count in the Sysmex XP-300 cell counter

**Table 1.** The patient's CBC result in different conditions

CBC test	Nihon Kohden Celltac G			Sysmex XP-300	Reference range
	Sample 1	Sample 2	Sample 3	Sample 4	
RBC ( $\times 10^{12}/L$ )	6.24	5.9	6.1	6.11	4.3–5.7
WBC ( $\times 10^9/L$ )	3.41	4.6	4.75	4.4	3.5–10.5
PLT ( $\times 10^9/L$ )	9.6	10.1	11	129	145–420
Hb (g/dL)	11.88	11.2	10.78	11.2	13.5–17.5
HCT (%)	37.9	36.6	35.5	37.5	38–51
MCV (fL)	60.7	63.8	61.5	64.0	81–95
MCH (pg)	19.0	19.5	18.7	19.6	27–33
MCHC (g/dL)	31.1	30.6	30.4	30.6	32–36

Abbreviations: Hb, hemoglobin; HCT, hematocrit; MCH, mean corpuscular hemoglobin; MCHC, mean corpuscular hemoglobin concentration; MCV, mean corpuscular volume; PLT, platelets; RBC, red blood cell; WBC, white blood cell.

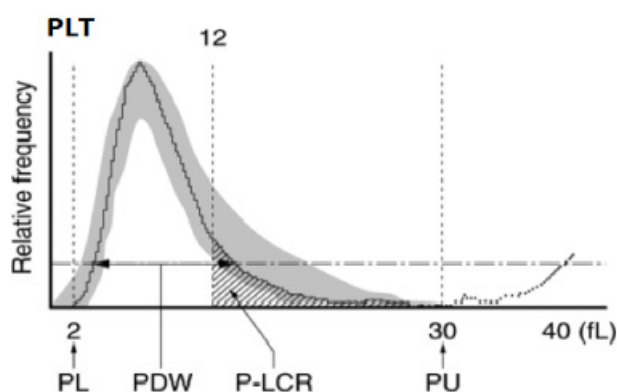
Sample 1: EDTA anticoagulant.

Sample 2: Repeated with EDTA anticoagulant.

Sample 3: Sodium citrate anticoagulant.

Sample 1, 2, and 3 analyzed by Nihon Kohden Celltac G

Sample 4: EDTA anticoagulant, analyzed by Sysmex XP-300 cell counter.



**Figure 2.** Typical platelet volume distribution in an automated hematology analyzer. Abbreviations: PDW, platelet distribution width; PL, lower discrimination for platelet volume distribution; P-LCR, platelet-large cell ratio; PU, upper discrimination for platelet volume distribution

fL), the Sysmex XP-300 instrument did not accurately determine the PU line in this patient. However, Nihon Kohden Celltac G cell counter reported accurate platelet counts due to the accurate determination of the PU line. This error occurred due to the patient's specific condition (microcytic RBC), and according to the range considered for the platelet size, some microcytic RBCs were counted as platelets by the Sysmex-XP300 instrument. However, the Nihon Kohden Celltac G cell counter was able to differentiate between the RBCs and platelets by changing the PU line discriminator.

It should be noted that both instruments were checked daily in terms of calibration, and their accuracy was confirmed with valid controls. To solve this problem, it is necessary to have operators who possess the required skills confirm the platelet count through PBS. However, we have new generation instruments equipped with light scattering technology that can address this issue. These instruments utilize light scattering technology to accurately count platelets and RBCs, eliminating any

errors caused by the interference of RBC and platelet sizes. This error is also seen in hemoglobin H (Hb H) disease with very microcytic RBCs, causing a falsely high platelet count, which needs to be corrected by PBS examination.

Considering the clinical importance of platelet count, it is essential to consider various platelet count-related errors, such as PU errors. In addition, to avoid such errors, abnormal platelet counts should always be confirmed with PBS results. Finally, more advanced and updated cell counters are recommended in specialized medical centers.

## Conclusion

In the cases of poikilocytosis, such as microcytic RBCs in thalassemia and schistocytes in microangiopathic hemolytic anemia, physicians should assess the platelet and RBC histograms for the PU flag. In addition, abnormal platelet counts should be confirmed with PBS findings. Instruments with better resolution and diagnosis are recommended in specialized coagulation and hematology laboratories.

## Acknowledgements

We thank Gonabad University of Medical Sciences for their kind collaboration.

## Authors' Contribution

**Conceptualization:** Mohammad Ghorbani.

**Data curation:** Babak Mahmoudi, Abuzar Zakeri, Mohammad Reza Javan, Zahra Khoshnegah.

**Formal analysis:** Amin Solouki.

**Funding acquisition:** Mohammad Ghorbani.

**Investigation:** Amin Solouki, Mohammad Reza Javan, Hamid Reza Niazkar, Zahra Khoshnegah.

**Methodology:** Amin Solouki.

**Project administration:** Amin Solouki.

**Resources:** Mohammad Ghorbani.

**Supervision:** Amin Solouki, Amir Mohammad Solouki, Mohammad Ghorbani.

**Validation:** Amin Solouki.

**Visualization:** Amin Solouki.

**Writing–original draft:** Amin Solouki, Amir Mohammad Solouki.

**Writing–review & editing:** Amin Solouki, Amir Mohammad Solouki.

**Competing Interests**

The authors declare no conflict of interest.

**Ethical Approval**

Informed consent was obtained from the patient for the publication of his data.

**Funding**

None.

**References**

1. Brown BA, Hunter RC, O'Hare A, Erim G. Hematology: Principles and Procedures. Philadelphia: Lea & Febiger; 1993.
2. Bizzaro N. EDTA-dependent pseud thrombocytopenia: a clinical and epidemiological study of 112 cases, with 10-year follow-up. *Am J Hematol.* 1995;50(2):103-9. doi: [10.1002/ajh.2830500206](https://doi.org/10.1002/ajh.2830500206).
3. Briggs C, Harrison P, Machin SJ. Continuing developments with the automated platelet count. *Int J Lab Hematol.* 2007;29(2):77-91. doi: [10.1111/j.1751-553X.2007.00909.x](https://doi.org/10.1111/j.1751-553X.2007.00909.x).
4. Gupta A, Gupta P, Bhaghat VM. Interpretation of histograms and its correlation with peripheral smear findings. *J Evol Med Dent Sci.* 2017;6(60):4417-20. doi: [10.14260/Jemds/2017/955](https://doi.org/10.14260/Jemds/2017/955).
5. Athanasiou LV, Tsokana CN, Pardali D, Moraitou KA. Histograms of complete blood counts in dogs: maximizing diagnostic information. *Top Companion Anim Med.* 2018;33(4):141-6. doi: [10.1053/j.tcam.2018.06.001](https://doi.org/10.1053/j.tcam.2018.06.001).
6. van Dievoet MA, Louagie H, Ghys T. Performance evaluation of the Sysmex® XP-300 in an oncology setting: evaluation and comparison of hematological parameters with the Sysmex® XN-3000. *Int J Lab Hematol.* 2016;38(5):490-6. doi: [10.1111/ijlh.12522](https://doi.org/10.1111/ijlh.12522).
7. Mathers RA, Evans GO, Bleby J. Platelet measurements in rat, dog and mouse blood samples using the Sysmex® XT-2000iV. *Comp Clin Path.* 2013;22(5):815-21. doi: [10.1007/s00580-012-1483-9](https://doi.org/10.1007/s00580-012-1483-9).
8. Ghorbani M, Niazkar HR, Ejtehadi MM, Mahmoudi R, Abbasnezhad A. Can Macrothrombocytopenia Mislead the Treatment of Idiopathic Thrombocytopenia Purpura? *Iran J Blood Cancer.* 2018;10(4):133-5.