

Esthetic-based Dental Management of Dentinogenesis Imperfecta in a 2.5-year-old Child

Leyli Sadri ¹, Soroush Sadri ², Najmeh Akhlaghi ³, Hamid Sarlak ^{4*}

1. Department of Pediatric Dentistry, School of Dentistry, Mazandaran University of Medical Sciences, Mazandaran, Iran
2. Department of Physical medicine and Rehabilitation, School of Medicine, Isfahan University of Medical Sciences, Isfahan, Iran
3. Department of Pediatric Dentistry, Dental Research Center, School of Dentistry, Isfahan University of Medical Sciences, Isfahan, Iran
4. Department of Pediatric Dentistry, School of Dentistry, Arak University of Medical Sciences, Arak, Iran



ABSTRACT

Background: Dentinogenesis imperfecta (DI) is an autosomal dominant (AD) hereditary dentin disorder, which occurs in the absence of any systemic disorder. The patients with DI presented rapid and severe attrition in primary teeth, which causes functional disorders and unusual discomfoting appearance.

Case presentation: The purpose of this case report was to describe the clinical, radiographical, Familial, histopathological, and genotype characteristics of a 2.5-year-old boy with early diagnosis of dentinogenesis imperfecta type II. In this case, it was also presented an uncommon and novel treatment method to promote function and esthetic of dentinogenesis imperfecta patients with 18-month follow up. The treatment plan included two major phases: 1) Restoring badly destroyed teeth by stainless steel crowns to reconstructed ideal function and 2) Using Wiedenfeld's method for making the appearance of anterior teeth better and acceptable.

Conclusion: Combination of "restoring destroyed teeth by steel crowns" and "using Wiedenfeld's method for anterior teeth" provided function and esthetic successfully for patients with dentinogenesis imperfecta.

Keywords: Dentin, Dentinogenesis imperfecta, Developmental anomaly, Esthetics, Pediatric dentistry

Citation: Sadri L, Sadri S, Akhlaghi N, Sarlak H. Esthetic-based dental management of dentinogenesis imperfecta in a 2.5-year-old child. Journal of Kerman University of Medical Sciences 2021; 28(6): 603-609. doi:

Received: 14.04. 2021

Accepted: 13.09. 2021

***Correspondence:** Hamid Sarlak; Email: Dr.hamidsarlak@yahoo.com

Published by Kerman University of Medical Sciences

Introduction

Dentinogenesis imperfecta (DI) is an autosomal dominant (AD) hereditary disorder of dentin formation with high penetrance and a low mutation rate, which occurs in the absence of any systemic disorder (1).

The clinical manifestation of DI is an amber like translucency varying from gray to brown. The enamel might have peeled off to leave dentin exposed, making it susceptible to severe and rapid attrition (2, 3).

Radiographic features of DI include normal enamel radiodensity and thickness, bulbous crowns, and partial or total progressive obliteration of pulpal space (4). The teeth have significant attrition that can be seen over a short period of time (5).

Dentin sialophosphoprotein gene (Gene map locus 4q12-q21) mutation (6) causes a defect in two dentin proteins: Dentin sialophosphoprotein (DSP) and dentin phosphoprotein (DPP) that is responsible for 50% of non-collagenous structure of dentin (7).

Dentinogenesis imperfecta has been classified by Shields (8) into three types: Type I occurs with osteogenesis imperfecta. Permanent teeth are affected milder than primary teeth due to thicker enamel. Type II is also known as heredity opalescent dentin, in which both primary and permanent dentitions are equally affected. Type III is rare and has occurred exclusively in the city of Brandywine, where there was a large population of patients, with a shell-like appearance, especially in the permanent dentition (7, 8).

All of the three types of DI demonstrate similar changes in dentin structure histologically (9). Normal mantle dentin, irregular circum pulpal dentin with sparse, and irregular dentinal tubules, often with large areas of uncalcified matrix are the histologic features (10).

Early diagnosis and proper treatment are mandatory to achieve better functional and esthetic results. The purpose of this case report was to describe the characteristics of a case of DI and to discuss the treatment plan.

Case Report

Clinical examination: A 2.5-year-old male patient reported to the Pediatric Department of Isfahan Dental School, Isfahan, Iran, complaining of abnormal appearance of teeth. An intraoral examination revealed attrition of the primary teeth. His teeth appeared reddish-brown with an opalescent translucent hue and complete loss of enamel in most cases, and exposed dentin was visible. The patient was generally in good health and did not currently take any medication (Figure 1).

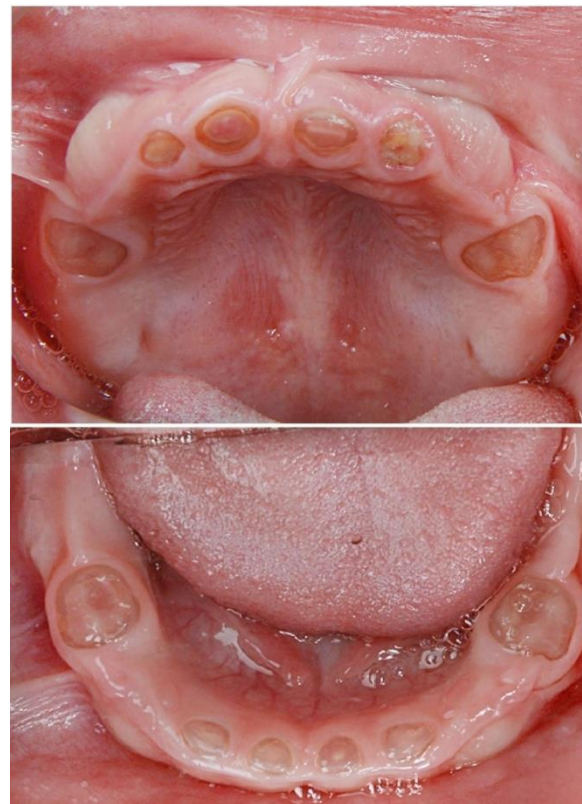


Figure 1. Clinical view of the patient at the first visit (2.5 years old).

Radiographic examination: Panoramic radiograph revealed severe attrition with no enamel, wide canals of teeth with incompletely formed roots. There were no evidences of obliteration or periapical pathology. Alveolar bone was normal (Figure 2).

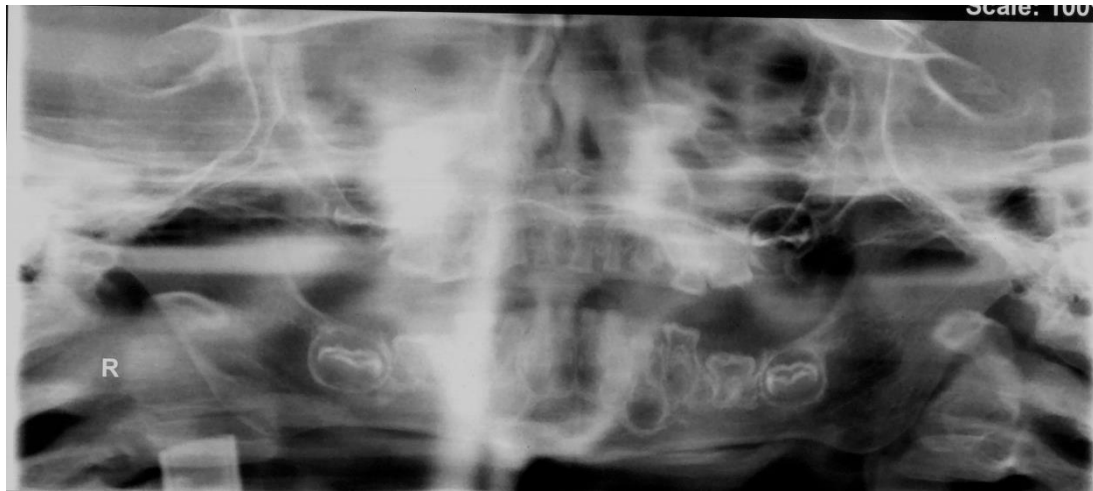


Figure 2. Panoramic radiograph of the 2.5-year-old child.

Family history: His parents had not a consanguineous marriage. There was no history of any unusual teeth appearances in the family, or any other systemic illness or drug use in the present or past.

Histopathology: Histologic examination of maxillary anterior-extracted teeth in the first

stage of treatment plan showed numerous globular and interglobular dentin with a few disorganized increased caliber tubular structures, which was more prominent in circumpulpal dentin compared to the mantle dentin. The dentino-enamel junction (DEJ) was straight smooth in some locations (Figure 3).

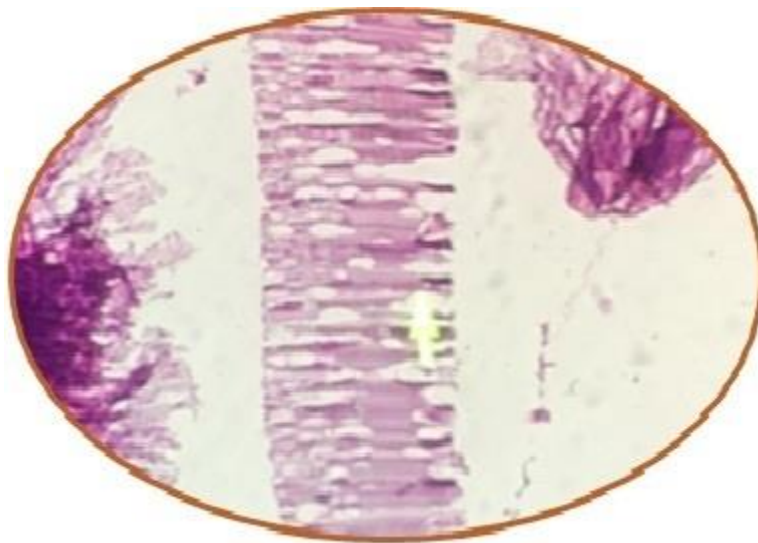


Figure 3. Histopathological view of extracted maxillary incisors.

Molecular analysis report: DNA was extracted from blood sample and DSPP gene was analyzed by PCR Device (PCR System, Applied Biosystems, Waltham, USA) and sequencing device (ABI prism 3730 sequencer, Applied Biosystems, Waltham, USA) for both DNA strands of the entire coding region and the highly conserved exon-intron splice junction. The reference sequence is: DSPP: NM_014208.3. Thus, the patient was heterozygous for likely pathogenic variant of c.49C>T (p.Pro 7 Ser) and a genetic diagnosis of DI was confirmed. The

analysis and report were performed by Genetic Counseling Center (Dr. Nouri Isfahan, Iran).

Treatment plan: As the patient was very young and uncooperative, the treatments were performed under general anesthesia. Four stainless steel crowns (SSC) (3M/ ESPE, St. Paul MN, USA) was placed for the first molars without occlusal reduction with the aim of bite-reconstruction. The maxillary incisors were extracted due to their extreme crown destruction and pulp exposure and used for histopathological examination. After 6 months, the second primary

molars and canines were erupted that should be treated as soon as possible (Figure 4). The second molars were restored with SSC immediately after eruption under sedation using Midazolam (0.25-1 mg/kg -0.5 ml dosage). Due to emphasizing on the esthetic-aspects, the maxillary primary canines were restored with chairside veneering of well-adjusted SSC method (first described by Wiedenfeld et al.) to rebuild function and esthetic of anterior segment (11). For a better result, it was decided to use the newest paper related to this method (12), and so the new adhesive system, Scotchbond universal adhesive (3M ESPE, Seefeld, Germany), was used. Following adjustment of SSCrowns on upper Canines, the crowns were sandblasted and cemented in a proper position, and then, this

technique was completed on another day. According to the manufacturer's instructions, cemented crowns were etched with 37% phosphoric acid for 20 seconds for cleaning the surface, and then, Scotchbond Universal Adhesive was applied to the buccal surface of SSCs using a micro-brush. After 10 seconds of waiting, it was gently air sprayed, and cured for 30 seconds. Filtek Z350 composite resin (3M, St. Paul, MN, USA) was then applied to buccal surface of SSC and light cured for 40 seconds. Finally, alginate impressions were made and maxillary fixed palatal retainer with incisors pontics and stainless steel bands placed on the maxillary second molars were constructed to prevent space closure and to restore normal appearance (Figure 5).

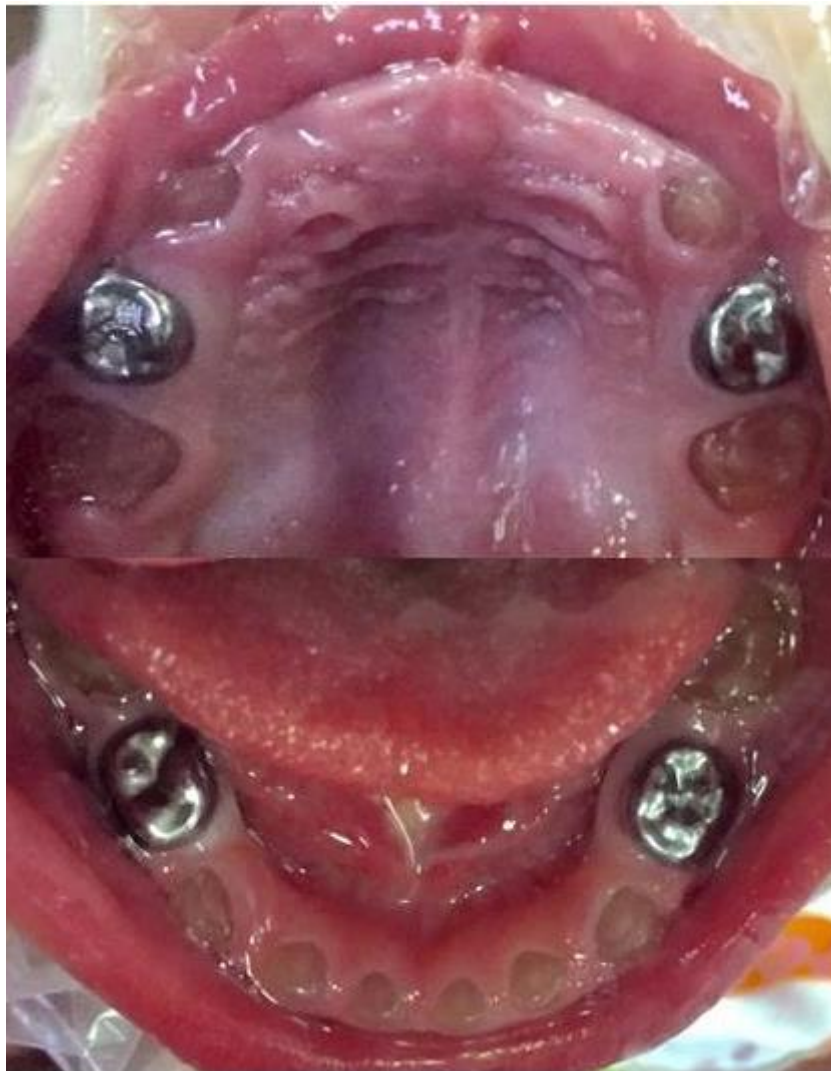

Figure 4. The primary second molars and canines erupted and should be treated.

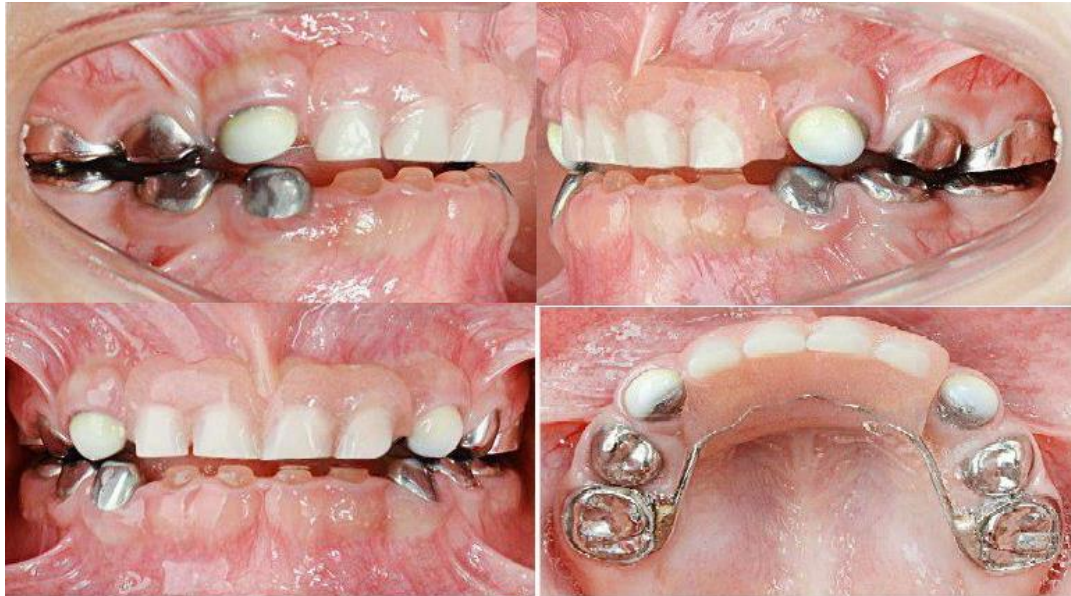

Figure 5. Upper canines were restored with SSCrowns and had been veneered by composite (Weildenfield's technique). Fixed esthetic appliance constructed for providing normal appearance and maintain arch circumference.

It should be noted that this child was uncooperative. Therefore, the treatment sessions had to be performed using the behavior modification and limitation methods such as Papoose Board (Olympic Medical Corp., Seattle, Wash), Molt Mouth Prop (Hu-Friedy, Chicago, III), and sedation.

The patient was under regular follow up every 3-month and had not any sign or symptom of soft tissue inflammation after 18 month and the radiographic view was in normal condition at this time (Figure 6). It is suggested that this treatment plan can be changed to removable denture in the future if the child cooperation becomes better.

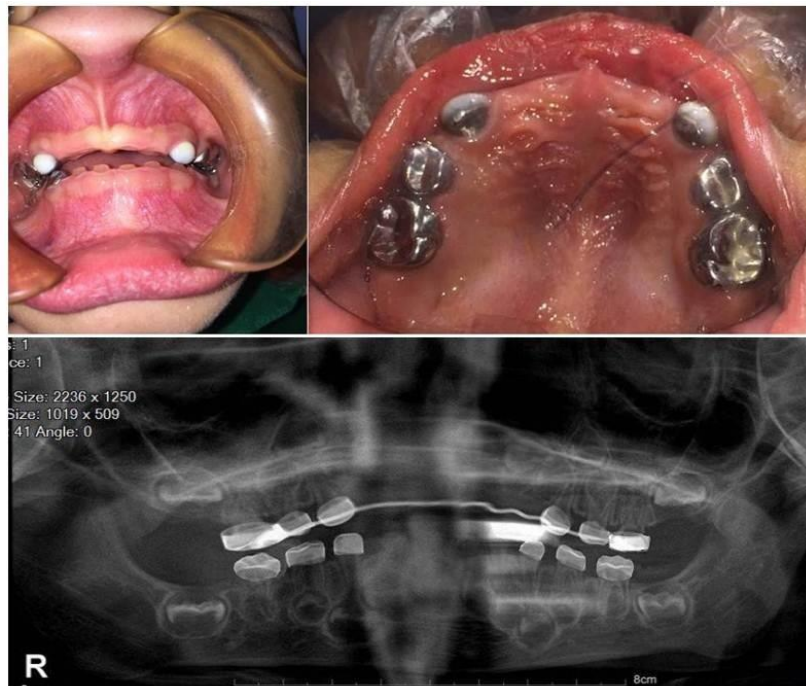


Figure 6. Recall panoramic radiograph and intra-oral photography of patient at the age of 4 years without fixed appliance (temporary removal for soft tissue examination).

Discussion

The aims of dental treatment for children with DI were to provide a good esthetic result and restore function (1). Timely diagnosis and appropriate treatment are essential for obtaining a favorable prognosis, which is a great psychological promotion to the patient's well-being.

The treatment planning for DI dictated by the age at the time of admission, clinical presentation, patient's expectations, severity and available resources (1, 13, 14). The possibility of optimal treatment for the patient decreases with aging (1, 13, 15). Fortunately, the first visit of this patient occurred in good time, thus, an early diagnosis and treatment could be performed. Except for maxillary incisors, the pulp of other teeth was not exposed yet. In order to prevent excessive loss of tooth structure, placement of SSC on deciduous posterior teeth is recommended as soon as the teeth erupts (2, 16). In this case, primary molars exhibited excessive attrition with enamel fracture. Hence, crowns were fabricated for all the primary molars to rehabilitate the occlusal height (bite). Fortunately, the pulp of molars had been not exposed. Follow-up visits are inevitable (2). Informed consent was recorded. When wear occurs toward or below the gingival line, exodontia is indicated (17, 18), as in this case, the maxillary incisors. As a result of the decreased hardness of dentin, the restorations will not be permanent, thus, follow-up visits are inevitable (2). Informed consent was recorded. When wear occurs toward or below the gingival line, exodontia is indicated (17, 18), as in this case, the maxillary incisors.

One of the challenges for this patient was the diagnosis of type 2 or 3 DI. In DI types 1 and 2, Sheild's teeth have usually bulbous crowns with a progressively obliterate pulp chambers and canals. Unlike types 1 and 2, type 3 involves teeth with a shell-like appearance and multiple pulp exposures especially in the permanent dentition. It has occurred exclusively in a

triracial isolated group in Maryland known as the Brandywine population (8, 10).

Some studies have declared that enamel pitting and periapical radiolucencies on teeth without pulpal exposure, and the enlarged pulp early in tooth development were the characteristics of type 3 DI (19). However, it seems that this case was type 2 DI and due to early age of the patient, pulp chambers were normally wide and roots had been not closed yet, resembling "shell teeth" with no periapical radiolucencies. Molecular analysis was performed to establish the differential diagnosis and DI was confirmed. Large areas of unmineralized dentin and irregular border between the unmineralized and mineralized dentin was seen histologically as well. In genetic consultation, the parents were recommended to visit in 5-7 weeks of next pregnancy to prevent such disease in their next pregnancy.

The traditional treatment plans of DI patient were based on functional aspects without considering cosmetic importance (13, 15, 16). A recent case report study has described CAD/CAM approach for rehabilitation of early aged DI patients and reported satisfactory outcomes although the main disadvantage of this approach is expense of related devices (4). Based on our successful and esthetic-based treatment for upper canines in this case, Weildenfield's technique is proposed to improve SSCrowns's appearance and color in esthetic zone of DI patients instead of cutting the crown and not excellent view in open-faced technique. In addition to reconstruction of normal appearance, it is proposed to consider restore anterior primary teeth in treatment planning for emphasis on psychological aspect of DI patients, and because of no evidence of growth restriction by fixed appliance and minimal intercanine growth between 2 to 4 years (≤ 0.5 mm) (20), we compromised this insignificant problem.

Conflict of interests

The authors declare that there is no conflict of interests.

References

1. Barron MJ, McDonnell ST, Mackie I, Dixon MJ. Hereditary dentine disorders: dentinogenesis imperfecta and dentine dysplasia. *Orphanet J Rare Dis.* 2008; 3:31. doi: 10.1186/1750-1172-3-31.
2. Beattie ML, Kim JW, Gong SG, Murdoch-Kinch CA, Simmer JP, Hu JC. Phenotypic variation in dentinogenesis imperfecta/dentin dysplasia linked to 4q21. *J Dent Res.* 2006; 85(4):329-33. doi: 10.1177/154405910608500409.

3. Shi S, Li N, Jin X, Huang S, Ma J. A Digital Esthetic Rehabilitation of a Patient with Dentinogenesis Imperfecta Type II: A Clinical Report. *Journal of Prosthodontics*. 2020; 29(8):643-50. doi:10.1111/jopr.13237.
4. Sarapultseva M, Leleko A, Sarapultsev A. Case report: Rehabilitation of a child with dentinogenesis imperfecta with CAD/CAM approach: Three-year follow-up. *Spec Care Dentist*. 2020; 40(5):511-518. doi: 10.1111/scd.12500.
5. Biria M, Abbas FM, Mozaffar S, Ahmadi R. Dentinogenesis imperfecta associated with osteogenesis imperfecta. *Dent Res J (Isfahan)*. 2012; 9(4):489-94. PMID: 23162594
6. Thotakura SR, Mah T, Srinivasan R, Takagi Y, Veis A, George A. The non-collagenous dentin matrix proteins are involved in dentinogenesis imperfecta type II (DGI-II). *J Dent Res*. 2000; 79(3):835-9. doi: 10.1177/00220345000790030901.
7. MacDougall M, Jeffords LG, Gu TT, Knight CB, Frei G, Reus BE, Otterud B, Leppert M, Leach RJ. Genetic linkage of the dentinogenesis imperfecta type III locus to chromosome 4q. *J Dent Res*. 1999; 78(6):1277-82. doi: 10.1177/00220345990780061301.
8. Shields ED, Bixler D, el-Kafrawy AM. A proposed classification for heritable human dentine defects with a description of a new entity. *Arch Oral Biol*. 1973; 18(4):543-53. doi: 10.1016/0003-9969(73)90075-7.
9. Seow WK. Developmental defects of enamel and dentine: challenges for basic science research and clinical management. *Aust Dent J*. 2014; 59:143-54. doi: 10.1111/adj.12104.
10. McDonald RE, Avery DR, Stookey GK, Chin JR, Kowolik JE. *Dental caries in the child and adolescent. McDonald and Avery Dentistry for the Child and Adolescent*: Elsevier Inc; 2011.
11. Wiedenfeld KR, Draughn RA, Welford JB. An esthetic technique for veneering anterior stainless steel crowns with composite resin. *ASDC J Dent Child*. 1994; 61(5-6):321-6. PMID: 7896998.
12. Ghadimi S, Heidari A, Sarlak H. Comparison of shear bond strength of composite to stainless steel crowns using two mechanical surface treatments and two bonding systems. *J Dent (Tehran)*. 2016;13(1):60. PMID: 27536330.
13. Akhlaghi N, Eshghi A-R, Mohamadpour M. Dental management of a child with dentinogenesis imperfecta: A case report. *J Dent (Tehran)*. 2016; 13(2):133. PMID: 27928242.
14. Sapir S, Shapira J. Dentinogenesis imperfecta: an early treatment strategy. *Pediatr Dent*. 2001; 23(3):232-7. PMID: 11447953.
15. Delgado AC, Ruiz M, Alarcón JA, González E. Dentinogenesis imperfecta: the importance of early treatment. *Quintessence Int*. 2008; 39(3):257-63. PMID: 18618042.
16. Huth KCh, Paschos E, Sagner T, Hickel R. Diagnostic features and pedodontic-orthodontic management in dentinogenesis imperfecta type II: a case report. *Int J Paediatr Dent*. 2002; 12(5):316-21. doi: 10.1046/j.1365-263x.2002.00390.x.
17. Crowell MD. Dentinogenesis imperfecta: a case report. *Am J Orthod Dentofacial Orthop*. 1998; 114(4):367-71. doi: 10.1016/s0889-5406(98)70180-5.
18. Subramaniam P, Mathew S, Sugnani SN. Dentinogenesis imperfecta: a case report. *J Indian Soc Pedod Prev Dent*. 2008; 26(2):85-7. doi: 10.4103/0970-4388.41624.
19. Levin LS, Leaf SH, Jelmini RJ, Rose JJ, Rosenbaum KN. Dentinogenesis imperfecta in the Brandywine isolate (DI type III): clinical, radiologic, and scanning electron microscopic studies of the dentition. *Oral Surg Oral Med Oral Pathol*. 1983; 56(3):267-74. doi: 10.1016/0030-4220(83)90008-7.
20. Waggoner WF, Kupietzky A. Anterior esthetic fixed appliances for the preschooler: considerations and a technique for placement. *Pediatr Dent*. 2001; 23(2):147-50. PMID: 11340729.