

Myofibroblasts in Calcifying Odontogenic Cyst and Dentigerous Cyst

Negin Mansuri, ¹, Hamid Abbaszadeh, Ph.D. ², Majid Sharbatdaran, Ph.D. ³, Nasrollah Saghravanian, Ph.D. ⁴,
Hemmat Gholinia, M.Sc. ⁵

1- Student Research Committee, Faculty of Dentistry, Babol University of Medical Sciences, Babol, Iran

2- Assistant Professor, Cellular and Molecular Biology Research Center, Health Research Institute, Babol University of Medical Sciences, Babol, Iran
(Corresponding author; E-mail: hamidabbaszade@yahoo.com)

3- Department of Pathology, Faculty of Medicine, Babol University of Medical Sciences, Babol, Iran

4- Assistant Professor, Department of Oral and Maxillofacial Pathology, Faculty of Dentistry, Mashhad University of Medical Sciences, Mashhad, Iran

5- Health Research Institute, Babol University of Medical Sciences, Babol, Iran

Received: 20 June, 2018

Accepted: 16 July, 2018

ARTICLE INFO

Article type:

Original Article

Keywords:

Calcifying odontogenic cyst

Dentigerous cyst

Myofibroblasts

Abstract

Introduction: Calcifying odontogenic cyst (COC) is an odontogenic cyst that sometimes shows aggressive behavior, while dentigerous cyst (DC) always has a benign nonaggressive course. There are evidences that myofibroblasts are involved in invasion and their role in biologic behavior of odontogenic cysts has been less understood. So, the aim of the present study was to compare the role of myofibroblasts in COC and DC.

Methods: In this cross-sectional study, paraffin-embedded tissue blocks of 20 COCs and 20 DCs were studied. Four-micron sections were prepared from tissue blocks and stained with α -SMA antibody using immunohistochemistry. Percentages of myofibroblasts were semi quantitatively classified into negative (<5% of cells were positive), weak (5-50% cells were positive) and strong (>50% of cells were positive). Percentage of myofibroblasts was compared between COC and DC groups using t-test and Chi-Square statistical tests.

Results: Means of myofibroblasts percentages in COC and DC groups were respectively 35 ± 33 and 32 ± 30 that did not show significant difference between COC and DC groups ($P=0.76$). There was not any significant difference between COC and DC groups with respect to semi quantitative classification of percentage of myofibroblasts ($P=0.62$).

Conclusion: Myofibroblasts probably do not play a significant role in different biologic behaviors of calcifying odontogenic and dentigerous cysts.

Copyright: 2018 The Author(s); Published by Kerman University of Medical Sciences. This is an open-access article distributed under the terms of the Creative Commons Attribution License (<http://creativecommons.org/licenses/by/4.0>), which permits unrestricted use, distribution, and reproduction in any medium, provided the original work is properly cited.

Citation: Mansuri N, Abbaszadeh H, Sharbatdaran M, Saghravanian N, Gholinia H. Myofibroblasts in Calcifying Odontogenic Cyst and Dentigerous Cyst. Journal of Kerman University of Medical Sciences, 2018; 25 (5): 441-445.

Introduction

Odontogenic cysts are among the most frequent destructive lesions of jaws which their pathogenesis and growth mechanism have not been cleared (1). Calcifying

odontogenic cyst (COC) is characterized with the presence of ghost cells in epithelial lining of the cyst (2). It has diverse clinical presentations, radiographic features and biological behaviors (3). It sometimes recurs and World Health Organization (WHO) has classified COC as a neoplasm and

hence the term “calcifying cystic odontogenic tumor” has been suggested for this cyst (4). On the other hand, dentigerous cyst (DC) is a developmental odontogenic cyst which behaves in a nonaggressive fashion and its prognosis is excellent and seldom recurs (2). So, the biologic behavior and prognosis of these two cysts are different.

Myofibroblasts are fibroblasts that have been specialized by producing TGF β -1 and have structural properties of smooth muscle including α -smooth muscle actin expression (5). Myofibroblasts are present within normal tissues such as blood vessels, submucosa of uterus and lungs and can be found in pathologic conditions like benign tumors, locally aggressive fibromatosis and sarcomas (6). There are evidences that the presence of myofibroblasts is not part of host response against tumor but indeed cause invasion and progression of tumor (7).

Role of myofibroblasts in invasion of odontogenic cysts is a concept which has recently taken into account (8-10). So, the aim of the present study was to immunohistochemically evaluate the presence of myofibroblasts in calcifying odontogenic cyst to understand the probable role of myofibroblasts in aggressive behavior of this odontogenic cyst.

Materials & Methods

In this cross-sectional retrospective study, two groups of paraffin-embedded tissue blocks of 20 calcifying odontogenic cysts (odontogenic cysts with aggressive behavior) and 20 non-inflamed dentigerous cysts (odontogenic cysts with nonaggressive behavior) were studied. Samples were retrieved from archive of oral and maxillofacial pathology departments at Babol and Mashhad dental faculties.

Four-micron sections were prepared from tissue blocks and stained with α -SMA antibody (Bond™ Ready-to-Use Primary Antibody Smooth Muscle Actin [alpha sm-1]: a mouse anti-human monoclonal antibody; Leica Biosystems, Newcastle, United Kingdom, Product Code: PA0.943 Clone: alpha sm-1, Ig Class: IgG2a) using immunohistochemistry. A tissue sample from intestinal wall was used as external positive control for α -SMA and omission primary antibody

was used as negative control. Smooth muscle cells of blood vessel walls were considered as internal positive controls (5).

Spindle stromal cells which showed distinct positive cytoplasmic staining for α -SMA were considered as myofibroblasts (5). α -SMA+ smooth muscle cells of blood vessels' walls were not considered in this calculation (5).

For immunohistochemical analysis, numeration of myofibroblasts was done under light microscope (Olympus CX21, Tokyo, Japan) from the field immediately beneath the lining epithelium at 400 \times magnification (9). Ten successive high-power fields (HPFs) were chosen for each sample. The percentage of positive cells in each field was calculated. The mean percentage of 10 HPFs was considered as α -SMA expression for each case. Percentages of myofibroblasts were semi quantitatively classified into negative (<5% of cells were positive), weak (5-50% of cells were positive) and strong (>50% of cells were positive) (6, 10).

Data were analyzed statistically using SPSS20. The results were expressed as means \pm standard deviations (SD). Percentage of myofibroblasts was compared between COC and DC groups using t-test and Chi-Square statistical tests. $P < 0.05$ was considered significant.

Ethical Approvals

The study has been reviewed and approved by ethical board of Babol University of Medical Sciences (Code: MUBABOL.REC.1395.159).

Results

Of 20 COCs, 11 cases belonged to males and 9 cases to females. Twelve cases were located in maxilla and 8 cases were located in mandible. Most of the cases (18 cases) were located in the anterior portion of either jaw. The mean age of patients was 28 years old.

Of 20 DCs, 13 cases belonged to males and 7 cases to females. Fifteen cases were located in mandible and 5 cases were located in maxilla. Most of the cases (18 cases) were located in the posterior portion of either jaw. The mean age of patients was 25 years old.

Figure 1 and figure 2 show myofibroblasts in the cysts walls of calcifying odontogenic cyst and dentigerous cyst. Myofibroblasts were mostly located beneath the epithelial

lining of cysts in a parallel fashion in both COCs and DCs. However, bands of myofibroblasts were also observed in deeper portions of cysts walls.

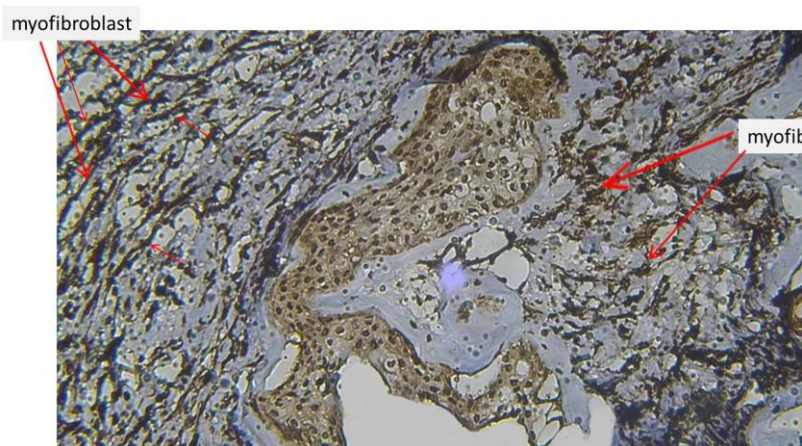


Figure 1: myofibroblasts in cyst wall of calcifying odontogenic cyst (100x magnification)

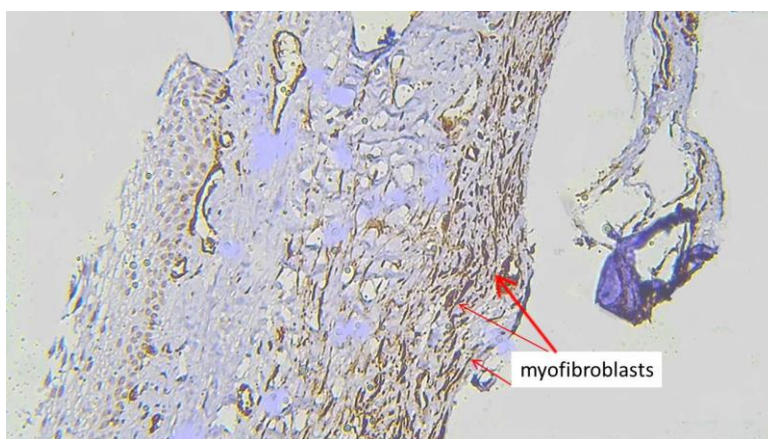


Figure 2: myofibroblasts in cyst wall of dentigerous cyst (100x magnification)

Three cases of DCs had no immunostaining for α -SMA and therefore myofibroblasts were not present in the cyst wall of these cysts. Myofibroblasts were not present in the cyst wall of 4 COCs.

Mean percentage of myofibroblasts in COCs and DC groups were 35 ± 33 and 32 ± 30 , respectively. Comparison of mean percentage of myofibroblasts by independent t-test did not reveal significant difference between COC and DC groups

($P=0.76$). Table 1 shows semi quantitative classification of percentage of myofibroblasts. According to this table, in most of COCs and DCs, percentages of myofibroblasts were within the weak category (5-50% of cells in cyst wall were myofibroblasts). According to chi-square statistical tests, there was not any significant difference between COC and DC groups with respect to semi quantitative classification of percentage of myofibroblasts ($P=0.62$).

Table 1: Comparison of percentage of myofibroblasts in calcifying odontogenic cyst and dentigerous cyst

group	percentage of myofibroblast			P value
	negative	weak	Strong	
COC*	4 20%	10 50%	6 30%	0.62
Dentigerous cyst**	3 15%	13 65%	4 20%	

* Calcifying odontogenic cyst

** Dentigerous cyst

Discussion

Calcifying odontogenic cyst (COC) and dentigerous cyst (DC) have different biologic behavior so that COCs could have aggressive behavior but dentigerous cysts almost always behave in a nonaggressive fashion. Myofibroblasts are cells that can cause invasion and progression in some aggressive benign and malignant tumors. In this study we assessed and compared the percentages of myofibroblasts in these two cysts.

Most of COCs and DCs in our study showed presence of myofibroblasts. Since myofibroblasts are considered reactive cellular component of stroma, this presence may reflect host response against cyst but it is more probably that these cells help the expansion and enlargement of the cysts. Mean percentages of myofibroblasts in these two cysts did not show significant difference; therefore, different biologic behaviors of COC and DC cannot be attributed to myofibroblasts and probably these cells do not play an important role in greater aggression and recurrence of COCs. Some previous studies on myofibroblasts in odontogenic cysts have shown significantly greater percentage of myofibroblasts in odontogenic keratocysts compared to other odontogenic cysts including dentigerous cyst and radicular cyst which coordinates with clinical aggressive behavior of odontogenic keratocysts (6, 8-

10). In these studies, odontogenic tumors especially ameloblastoma had more myofibroblasts than odontogenic cyst (radicular cyst, dentigerous cyst, unicystic ameloblastoma) (8-10). In Kouhsoltani M et al study, COC had significantly lower myofibroblast than dentigerous cyst (10). This finding is in contradiction with our results; this contradiction may be related to smaller study group in their study compared to our study. Moreover, due to more aggressive behavior of COC compared to DC, their finding is somewhat unlikely and does not coordinate with clinical behavior of these two cysts. Our finding is closer to the reality.

Conclusion

Myofibroblasts are present within cyst wall of most of COCs and DCs but do not play an important role in different biologic behaviors of these two cysts.

Acknowledgement

We thank Research Vice Chancellor of Babol University of Medical Sciences for supporting this study.

Conflict of interest

No conflict of interest

References

1. Rajabi-Moghaddam M, Abbaszadeh-Bidokhty H, Bijani A. Comparison of mast cells count in odontogenic cysts using histochemical staining. *Iran J Pathol*. 2015;10(2):105-110.
2. Neville BW, Daam DD, Allen CM, Chi AC. Oral and maxillofacial pathology. 4thed., Missouri, Saunders Co., 2016; PP 647-8.
3. Thinakaran M, Sivakumar P, Ramalingam S, Jeddy N, Balaguhan S. Calcifying ghost cell odontogenic cyst: A review on terminologies and classifications. *J oral maxillofac pathol* 2012; 16 (3):450-3.
4. Eshghyar N, Jalayer-Nadery N, Ashery R. Calcifying odontogenic cyst: an analysis of thirty-six cases. *Acta Medica Iranica* 2006 ;44 (1): 59-62.
5. Dodani A, Siadati S, Hajian-Tilaki K, Abbaszadeh H. Comparative evaluation of the frequency of myofibroblasts between oral and cutaneous squamous cell carcinomas. *Caspian J Dent Res* 2016; 5 (2):24-9.
6. Nadalin MR, Fregnani ER, Silva-Sousa YT, da Cruz Perez DE. Presence of myofibroblasts and matrix metalloproteinase 2 in radicular cysts, dentigerous cysts, and keratocystic odontogenic tumors: a comparative immunohistochemical study. *J endod* 2012; 38 (10):1363-7.
7. Mashhadiabbas F, Atarbashi Moghadam S, Moshref M, Elahi M. Immunohistochemical detection and ultrastructure of myofibroblasts in the stroma of odontogenic cysts and ameloblastoma. *Iran Red Crescent Med J* 2010; 12(4): 453-7.
8. Vered M, Shohat I, Buchner A, Dayan D. Myofibroblasts in stroma of odontogenic cysts and tumors can contribute to variations in the biological behavior of lesions. *Oral Oncol* 2005; 41 (10):1028-33.
9. Syamala D, Suresh R, Janardhanan M, Savithri V, Anand PP, Jose A. Immunohistochemical evaluation of myofibroblasts in odontogenic cysts and tumors: A comparative study. *J oral maxillofac pathol* 2016; 20(2): 208-13.
10. Kouhsoltani M, Halimi M, Jabbari G. Immunohistochemical evaluation of myofibroblast density in odontogenic cysts and tumors. *J Dent Res Dent Clin Dent Prospects* 2016;10(1):37-42.