

Abnormal Origin of Superior Laryngeal Artery and Its Clinical Significance: A Case Report

Abdolreza Babae, M.Sc.¹, Samereh Dehghani Soltani, M.Sc.¹, Seyed Hasan Eftekhari Vaghefi, Ph. D.², Seyed Shahaboddin Jahanbani, B.Sc.³, Massood Ezzatabadipour, Ph.D.⁴

1- Ph.D. candidate, Department of Anatomical Sciences, Afzalipour School of Medicine, Kerman University of Medical Sciences, Kerman, Iran.

2- Professor, Department of Anatomical Sciences, Afzalipour School of Medicine, Kerman University of Medical Sciences, Kerman, Iran.

3- M.Sc. student, Department of Anatomical Sciences, Afzalipour School of Medicine, Kerman University of Medical Sciences, Kerman, Iran.

4- Associate Professor, Department of Anatomical Sciences, Afzalipour School of Medicine, Kerman University of Medical Sciences, Kerman, Iran

(Corresponding author; E-mail: m_ezatabadi@kmu.ac.ir)

Received: 14 May, 2017

Accepted: 17 August, 2017

ARTICLE INFO

Article type:

Case Report

Keywords:

Superior laryngeal artery

Variation

Cadaver

Blood supply to the larynx

Abstract

Superior laryngeal artery (SLA) is one of the main branches of the superior thyroid artery that its main function is to supply blood to the larynx. This artery is accompanied by the internal branch of superior laryngeal nerve; this relation has anatomical and surgical significance. In this paper, a case of anomalous origin of the superior laryngeal artery is reported. Abnormal origin of SLA from the common carotid artery was observed in about 2cm before its branching point during dissection of the anterolateral region of the neck of a 70-year-old male cadaver through performing standard Grant's method. The SLA was traced until it passed through thyrohyoid membrane and entered the larynx. The abnormal origin of this artery from the lingual artery, external carotid artery, the facial and ascending pharyngeal artery had been previously reported.

A good understanding of the variation in origin of the SLA is necessary to avoid bleeding during surgery and also to avoid damage to the internal branch of the superior laryngeal nerve.

Copyright: 2017 The Author(s); Published by Kerman University of Medical Sciences. This is an open-access article distributed under the terms of the Creative Commons Attribution License (<http://creativecommons.org/licenses/by/4.0>), which permits unrestricted use, distribution, and reproduction in any medium, provided the original work is properly cited.

Citation: Babae A, Dehghani Soltani S, Eftekhari Vaghefi S.H, Jahanbani S.SH, Ezzatabadipour M. Abnormal Origin of Superior Laryngeal Artery and Its Clinical Significance: A Case Report. Journal of Kerman University of Medical Sciences, 2017; 24(3): 246-249.

Introduction

Superior laryngeal artery is one of the main arteries that supply blood to the laryngeal muscles and mucosa, and it is one of the main branches of the superior thyroid artery. Superior thyroid artery is one of the six branches of the external carotid artery (1, 2). The superior laryngeal artery is accompanied by the internal branch of the superior laryngeal nerve that after passing through thyrohyoid muscle, perforates

thyrohyoid membrane and enters the larynx. In the larynx, this artery is anastomosed to contralateral and inferior laryngeal arteries (3).

Arterial variation is one of the main issues in anatomy and surgery. Knowledge about artery variations in the neck, particularly the arteries that travel with their nerves, can prevent injuries to the patient during surgery; therefore, it has high clinical significance (4). The complications during the

surgery include bleeding and numbness of the larynx superior to the true vocal folds due to the damage to the internal branch of the superior laryngeal nerve after surgery. Laryngeal reconstruction and laryngectomy (removal of the larynx) are the main surgeries in which the position of superior laryngeal artery is very important (5, 6). Although variations of superior laryngeal artery are limited, in order to prevent complications after surgery and reduce bleeding during surgery, it is essential to study the vascular variations, especially arterial variations, more accurately. Here, we report another variation of the superior laryngeal artery.

Case Report

During dissection of the right side of the neck of a 70-year-old male cadaver that was performed in the dissecting room of Kerman School of Medicine, the anomalous origin of SLA from the common carotid artery in about 2cm before its branching point to the internal and external carotid arteries was observed. It passed posterior to the superior thyroid artery, perforated the thyrohyoid membrane, and entered the larynx (Figure 1 and 2).

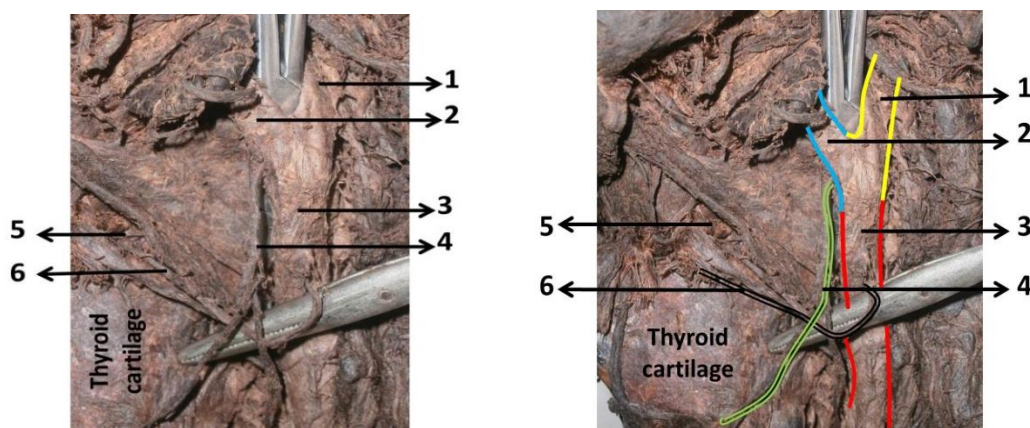


Figure 1. Anomalous origin of superior laryngeal artery from the common carotid artery; 1) Internal carotid artery; 2) External carotid artery; 3) Common carotid artery; 4) Superior thyroid artery; 5) Thyrohyoid membrane; 6) Superior laryngeal artery

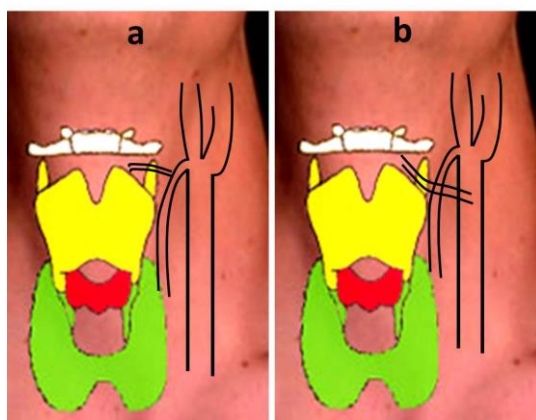


Figure 2. Comparison of the normal (a) and abnormal (b) origins of superior laryngeal artery

Discussion

Larynx is an important part of body which has a vital role in preventing the entry of foreign bodies into the lower respiratory tract and has a key role in audio production (7, 8). Keeping larynx function, particularly after surgery, depends on the accurate blood supply to larynx and its innervations (9, 10). Superior laryngeal artery mainly supplies blood to larynx and is normally originated from the superior thyroid artery (11). Damage to the superior laryngeal artery, during the surgery of neck and larynx, leads to bleeding and laryngeal ischemia (12, 13). Since internal branch of superior laryngeal nerve is accompanied by the superior laryngeal artery, any damage to this artery can be accompanied by damage to the superior laryngeal nerve; therefore, detecting the exact origin of this artery and its main path can improve the surgery prognosis and prevent damage to this artery (14). In the presented case, due to the abnormal origin of superior laryngeal artery, internal branch of superior laryngeal nerve, in part of its path, was completely separated from the artery and only at the distal end of its path was accompanied by the artery. Superior laryngeal nerve, as a branch of the Vagus nerve, has two branches (internal and external) in the neck.

The internal branch contains sensory fibers and along with superior laryngeal artery passes through the thyrohyoid membrane and involves in the larynx sensory innervation while the external branch contains motor fibers for cricothyroid muscle of the larynx. The abnormal origin of this artery from the lingual artery, external carotid artery, the facial and ascending pharyngeal artery have been reported. Lang et al (1986) reported that in 8.6% of the cases, superior laryngeal artery is directly originated from the external carotid artery (15). In another study, it was also reported that in 32% of the cases, this artery is originated from the external carotid artery (16). Nayak et al (2011) reported that in 5.4% of the cases, superior laryngeal artery is originated from lingual artery and in 2.7% of the cases, is originated from the common lingo-facio artery. However, based on the evidences, no similar arterial variations have been reported. Another variation of the superior laryngeal artery is that it has two branches of internal and external; therefore, in order to reduce bleeding during surgery, these two branches should be detected and closed (17, 18). Furthermore, superior laryngeal artery may originate from facial or ascending pharyngeal artery (19).

References

1. Patel JP, Dave RV, Shah RK, Kanani SD, Nirvan AB. A study of superior thyroid artery in 50 cadavers. 2013.
2. Vázquez T, Cobiella R, Marañillo E, Valderrama FJ, McHanwell S, Parkin I, et al. Anatomical variations of the superior thyroid and superior laryngeal arteries. *Head & neck*. 2009;31(8):1078-85.
3. Liu JL, Liang CY, Xiang T, Wang F, Wang LH, Liu SX, et al. Aberrant branch of the superior laryngeal artery passing through the thyroid foramen. *Clinical Anatomy*. 2007;20(3):256-9.
4. Anagnostopoulou S, Mavridis I. Emerging patterns of the human superior thyroid artery and review of its clinical anatomy. *Surgical and Radiologic Anatomy*. 2014; 36(1):33-8.
5. Dziegielewski PT, Ho ML, Rieger J, Singh P, Langille M, Harris JR, et al. Total glossectomy with laryngeal preservation and free flap reconstruction: objective functional outcomes and

- systematic review of the literature. *The Laryngoscope*. 2013; 123(1):140-5.
6. Kidwai SM, Parasher AK, Agbetoba AA, Iloreta AM, Govindaraj S, Miles BA. Sinus Disease following Total Laryngectomy: A Radiographic Review. *Otolaryngology-Head and Neck Surgery*. 2014; 151(1 suppl):P128-P.
 7. Goyal N, Yoo F, Setabutr D, Goldenberg D. Surgical anatomy of the supraglottic larynx using the da Vinci robot. *Head & neck*. 2014; 36(8):1151-56
 8. Sasaki CT, Young N, Matsuzaki H, Paskhover B. Anatomy of the human larynx. Rubin JS, Sataloff RT, Korovin GS *Diagnosis and Treatment of Voice Disorders*. 2014; 3:31-46.
 9. Lu WT, Sun SQ, Huang J, Zhong Y, Xu J, Gan SW, et al. An applied anatomical study on the external laryngeal nerve loop and the superior thyroid artery in the neck surgical region. *Anatomical science international*. 2014; 1-7.
 10. Su WF, Liu SC, Wang SD, Su WY, Ma KH, Huang TT. Nerve branches to the posterior cricoarytenoid muscle may complicate the laryngeal reinnervation procedure. *The Laryngoscope*. 2015; 125(2):419-23.
 11. Mahajan A, Patil S. Anomalous origin of superior thyroid artery and its significance. *International Journal of Clinical and Surgical Advances*. 2013; 1(1):115-
 12. Ozgur Z, Govsa F, Celik S, Ozgur T. Clinically relevant variations of the superior thyroid artery: an anatomic guide for surgical neck dissection. *Surgical and radiologic anatomy*. 2009; 31(3):151-9.
 13. Shaha AR. Revision thyroid surgery—technical considerations. *Otolaryngologic clinics of North America*. 2008; 41(6):1169-83.
 14. Markogiannakis H, Zografos G, Manouras A. Prevention of superior laryngeal nerve injury in thyroid surgery. *Hellenic Journal of Surgery*. 2015; 87(1):85-8.
 15. Lang J, Nachbaur S, Fischer K, Vogel E. The superior laryngeal nerve and the superior laryngeal artery. *Acta anatomica*. 1986; 130(4):309-18.
 16. Rusu M, Nimigean V, Banu M, Cergan R, Niculescu V. The morphology and topography of the superior laryngeal artery. *Surgical and Radiologic Anatomy*. 2007; 29(8):653-60.
 17. Nayak SR, Krishnamurthy A, Prabhu LV, Potu BK, Bagoji IB, Jiji P, et al. Variable origin of the superior laryngeal artery and its clinical significance. *Al Ameen Journal of Medical Sciences*. 2011; 4(1):6-9.
 18. Nayak BS, Soumya K. Neurovascular variations in the carotid triangle. *International Journal of Anatomical Variations*. 2008; 1.
 19. Terayama N, Sanada J, Matsui O, Kobayashi S, Kawashima H, Yamashiro M, et al. Feeding artery of laryngeal and hypopharyngeal cancers: role of the superior thyroid artery in superselective intraarterial chemotherapy. *Cardiovascular and interventional radiology*. 2006; 29(4):536-43.