

## Multiple Brain Abscesses: An Unusual Case

Alireza Vakilian<sup>1</sup>, Habib Farahmand<sup>2</sup>, Jafar Ahmadi Kahnali<sup>2</sup>, Tahereh Eslammanesh<sup>3</sup>, Sajad Rezvan<sup>4\*</sup>,  
Saeid Karimi Matloub<sup>5</sup>

1. Department of Neurology, School of Medicine, Non Communicable Disease Research Center, Rafsanjan University of Medical Sciences, Rafsanjan, Iran
2. Department of Radiology, School of Medicine, Rafsanjan University of Medical Sciences, Rafsanjan, Iran
3. Department of Pathology, School of Medicine, Rafsanjan University of Medical Sciences, Rafsanjan, Iran
4. Radiology Resident, Rafsanjan University of Medical Sciences, Rafsanjan, Iran
5. Student Research Committee, Faculty of Medicine, Qom University of Medical Sciences, Qom, Iran



### ABSTRACT

Brain abscess is a collection of pus with a vascular capsule beginning as a cerebritis at its early stage. The incidence rate of brain abscess is approximately 0.13-0.9 per 100,000 person-year. In 33% of cases, brain abscess is spread hematogenously, mostly with endocarditis (13%), pulmonary infection (8%), or dental infection (5%). Other cases are attributed to recent neurosurgeries (9%) or cranial traumas (14%). *Streptococcus* and *Staphylococcus* species are the most common microorganisms causing brain abscesses. The symptoms presented include headache, fever, nausea, vomiting, focal neurologic symptoms, lethargy, and seizure. In this study, a 44-year-old coal worker methadone-abuser man who was admitted with the presentation of altered mental status, headache, imbalance, and vertigo with widespread ring-enhancing lesions in his brain caused by multiple brain abscesses due to solitary lung abscess without pulmonary disease symptoms is reported. Altered consciousness and dysphagia were considered as a cause for his aspiration.

**Keywords:** Multiple brain abscesses, Hematogenous spread, Confusional state, Ring enhancing lesion

**Citation:** Vakilian A, Farahmand H, Ahmadi Kahnali J, Eslammanesh T, Rezvan S, Karimi Matloub S. Multiple brain abscesses: An Unusual Case. Journal of Kerman University of Medical Sciences 2022; 29(2): 175-182. doi: 10.22062/JKMU.2022.91897

**Received:** 12. 06. 2021

**Accepted:** 25. 08. 2021

**\*Correspondence:** Sajjad Rezvan; Email: [clinicalresearch0185@gmail.com](mailto:clinicalresearch0185@gmail.com)

Published by Kerman University of Medical Sciences

## Introduction

**B**rain abscess (BA) is a collection of pus with a vascular capsule beginning as a cerebritis at its early stage. The causes of abscess formation in the brain are classified into four groups including contiguous infection (odontogenic abscesses, sinusitis), hematogenous spread to the brain from a distant infection focus, the direct implant (trauma or neurosurgery), and peripheral nerves. The incidence rate of BA is approximately 0.13-0.9 per 100,000 person-year, and its mortality rate is higher than 20-70% at the mean age of 35-37 years. More than 30% of BA causes are cryptogenic (no primary site of infection or conditional state is found). Different microorganisms including bacteria, fungi, and parasites may form the brain abscess (1-2).

According to a meta-analysis evaluating 9,699 patients' reports, *Streptococcus* and *Staphylococcus* species were the most common microorganisms causing BA. A total of 8,134 of 9,484 patients (86%) had predisposing conditions, and the most common predisposing condition was the contiguous infection (3).

Retrospective analysis of 352 cases showed that otogenic BA was the most common infection source (4).

In a study of 715 brain abscess cases, 425 (60%) had tuberculosis and 289 (40%) were pyogenic, suggesting that tuberculous abscess was more common. A total of 407 (57%) were male and 308 (43%) were female. The age of presentation mostly included the second and third decades of life (5).

In 33% of cases, brain abscess is spread hematogenously, mostly with endocarditis (13%), pulmonary infection (8%), or dental infection (5%). Other cases are attributed to recent neurosurgeries (9%), or cranial traumas (14%) (2).

Lungs are an important source causing the hematogenous spread to the brain. Pulmonary abscess and empyema, especially in bronchiectasis cases can cause BA, which may be in multiple cranial sites and is passed mostly through the middle cerebral artery at the gray-white matter junction. Additionally, there are other sites of infection such as skin, pelvis, heart (endocarditis), and intra-abdomen (6).

The disease presentation includes diverse symptoms such as headache, fever, nausea, vomiting, focal neurologic symptoms, lethargy, seizure, and the third and sixth cranial nerve deficits. Acute severe headaches may occur due

to rupture of the abscess. Furthermore, BA could cause intracranial hypertension.

In general, clinical manifestations are associated with the size of the abscess, as well as the location and surrounding areas such as cisterns, ventricles, and cerebral venous sinus. For example, rupture of an abscess into the brain ventricle may cause ependymitis, ventriculitis, or even septic thromboembolism leading to obstruction of the transverse or sigmoid sinus, which causes edema, seizure, and raised intracranial pressure (7-9).

The triad of fever, headache, and focal neurological deficit is present only in 20% of BA patients (2).

In some cases, the clinical manifestation of BA is non-specific; therefore, it may be diagnosed at its late stages with a poor prognosis (10). The diagnosis of multiple BAs has rapidly increased with the use of computed tomography (CT) (11).

In a CT scan with IV contrast at the early stages of abscess formation in which inflammation of the brain occurs, a low-density irregular area is totally or partially enhanced. Then, when the vascular capsule is formed, there is a regular enhancement at the borders with 1-3 mm wall thickness (8).

The MRI feature of pyogenic abscesses is that the central area of liquefaction has high signals and the surrounding edematous brain tissue gives low signals on T1-weighted images. On T2-weighted images, the necrosis shows higher signals similar to the gray matter. Most abscesses have a rim that is likely to be formed by the collagen and inflammation caused by the free radicals and microscopic bleeding in the abscess wall. In a morphometric analysis of histologic sections, it was shown that the site of inflammation in tuberculous abscesses is significantly larger than it is in pyogenic abscesses (5).

The radiological appearance of the brain abscesses can be misdiagnosed as cystic glioma and metastasis (12).

This case presents the clinical, imaging, and histological features of an atypical form of multiple BAs due to the hematogenous spread from the lungs. The existence of non-infectious cases with similar symptoms, emphasizes the importance of timely diagnosis and management in this regard.

### Case Report

The patient was a 44-year-old coal worker man admitted with the presentation of altered mental status, headache, imbalance, and vertigo. The respiratory rate was irregular and decreased. Blood pressure was 100/50, pulse rate was 49, body temperature was 37°C, and pupils were miotic. He had no signs of focal neurological symptoms, fever, seizure, or vomiting.

He was a methadone addict with no other history of IV drug abuse or any medical treatment like corticosteroids. Moreover, he had

no previous admissions related to any neurological or even infectious diseases such as head, neck, lung, or heart infections.

There were no risk factors for cardiovascular diseases including hypertension, hyperlipidemia, diabetes mellitus, and repaired congenital heart disease.

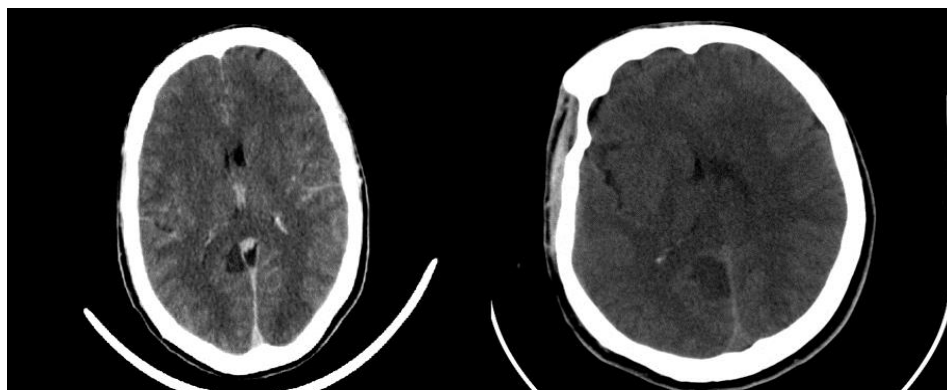
Anti-HIV, Anti-HBC, HBsAg, and other serological infective diseases' test results were negative. Other laboratory findings are shown in Table 1.

**Table 1.** Laboratory findings

W.B.C:10400 cells/ml	R.B.C:4.32 million/mc liter	HB:13 g(m/dl)	Hct:39%	MCV:91 fL/cell	plt:208000 /mcL	PT:12.8 Seconds
PTT:40 seconds	FBS:100 mg/dL	Urea :45 mg/dL	Cr:1	Na:137 mEq/L	K:4.5 mEq/L	

Radiography was needed for further evaluation, as the patient was agitated. Therefore, CT scans with and without IV

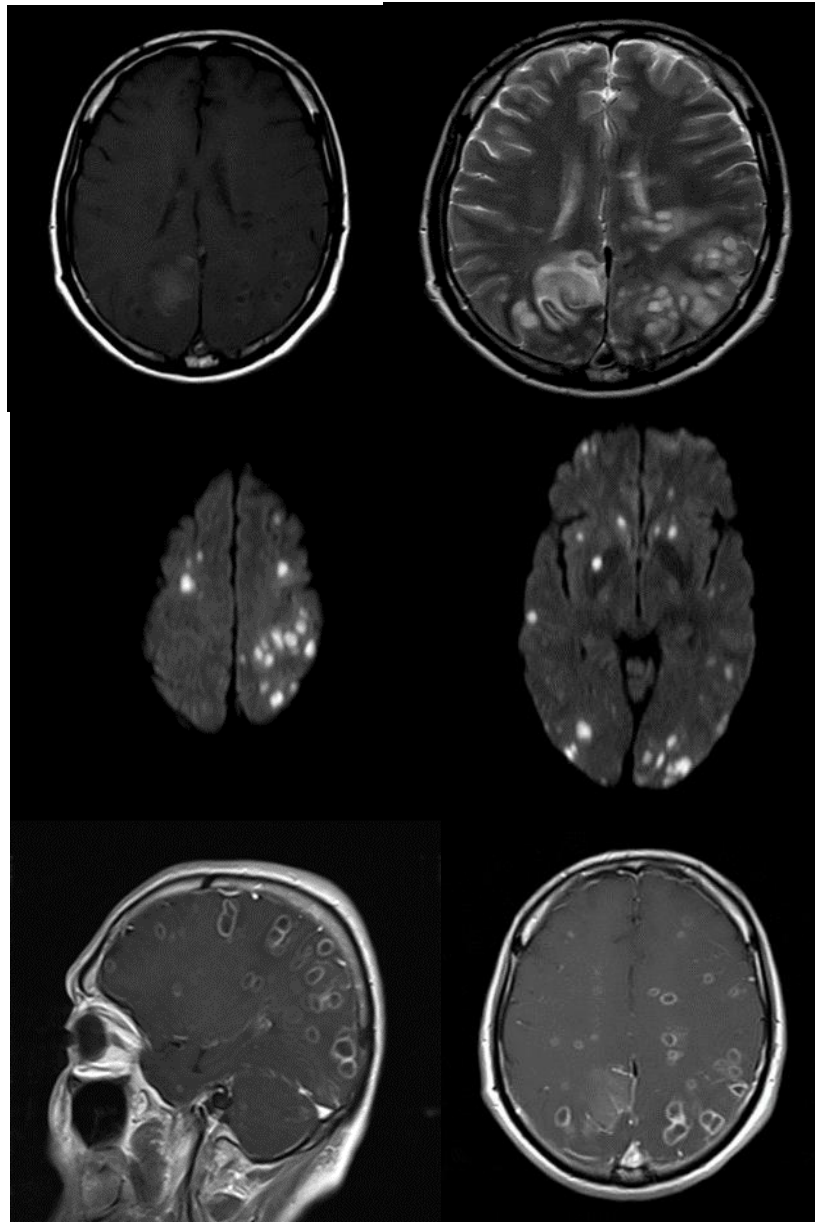
contrast were performed. The CT scan revealed some hypodense space-occupying lesions that were partially contrast-enhanced (Figure 1).



**Figure 1.** Brain CT scan without and with IV contrast demonstrated some ill-defined hypodense occupying lesions that were partially contrast-enhanced.

Based on the clinical symptoms, he initially took dexamethasone. After a few days, when his anxiety subsided and he became stable, a brain picture was taken from his brain using MRI, which revealed multiple T1 isodense and T2-FLAIR hyperintense lesions with peripheral edema. Some of the lesions in the bilateral

cerebral hemispheres, right basal ganglia, and right cerebellar hemisphere showed restriction in DWI. The signal change was seen at the right occipital lobe, indicating a peripheral restriction in favor of cerebritis. The first diagnosis was an infectious process (Figure 2).



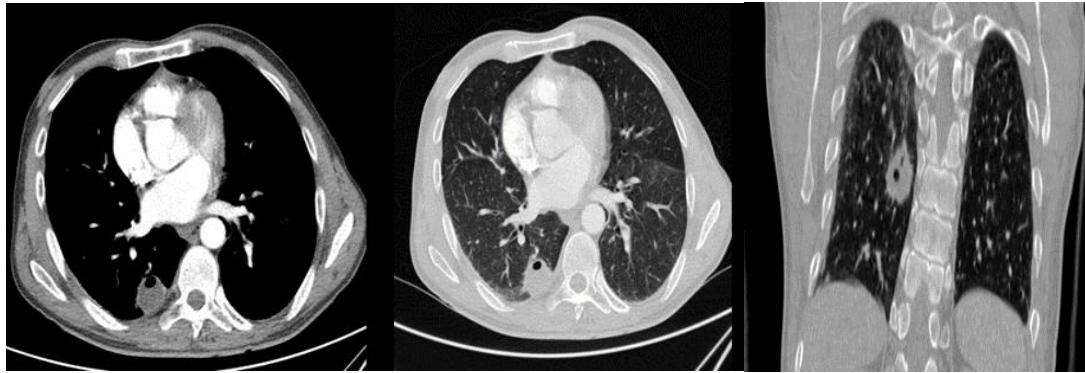
**Figure 2.** Multiple T1 isointense and T2-FLAIR hyperintense lesions with peripheral edema, some lesions in the bilateral cerebral hemispheres, and the right basal ganglia showed restriction at DWI. The signal change was seen at the right occipital lobe, indicating a peripheral restriction in favor of cerebritis. Post-contrast images showed the pattern of ring enhancement.

Echocardiography showed no evidence of endocarditis. There was no cardiac vegetation.

Since an associated cause of a patient's history with multiple intracranial abscesses could be immunosuppressive diseases such as HIV and Hepatitis B or C, the serological infective diseases such as anti-HIV, anti-HBC, HBsAg, etc., were tested but all results were negative.

Furthermore, the chest and abdomen CT scan was performed to evaluate the primary infection

source for multiple BAs. Atelectasis was seen in both lower lobes of the lungs. Moreover, a cavitory lesion containing air and fluid was seen in the right lower lobe approving the lung abscess. Focal traction bronchiectasis was seen at the right upper lobe. The abdominopelvic CT scan result was normal. There was no mass or lymphadenopathy in the abdomen or pelvis. There was no evidence of ascites (Figure 3).

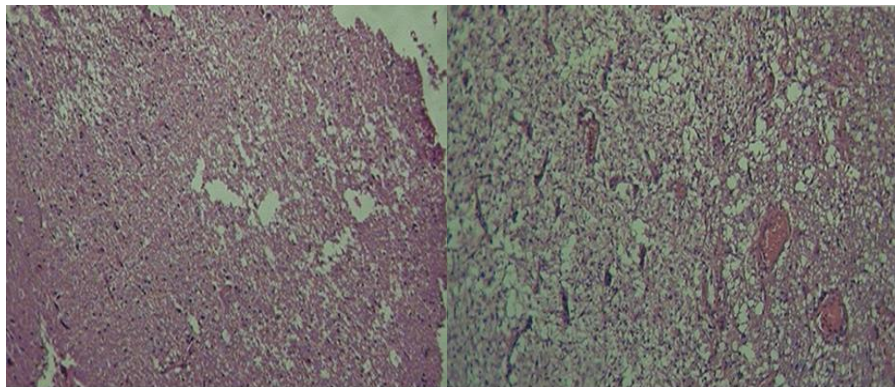


**Figure 3.** Cavitary lesion containing air and fluid was seen in the right lower lobe in favor of lung abscess.

Through microbiological inspections, we could not find a specific germ causing the lung abscess. It might have been polymicrobial with the dominance of anaerobe germs due to probable aspiration of oral contents in the confusional state.

Finally, the brain biopsy was carried out. The results of microscopic inspections showed small aggregation of neutrophils, necrotic tissue,

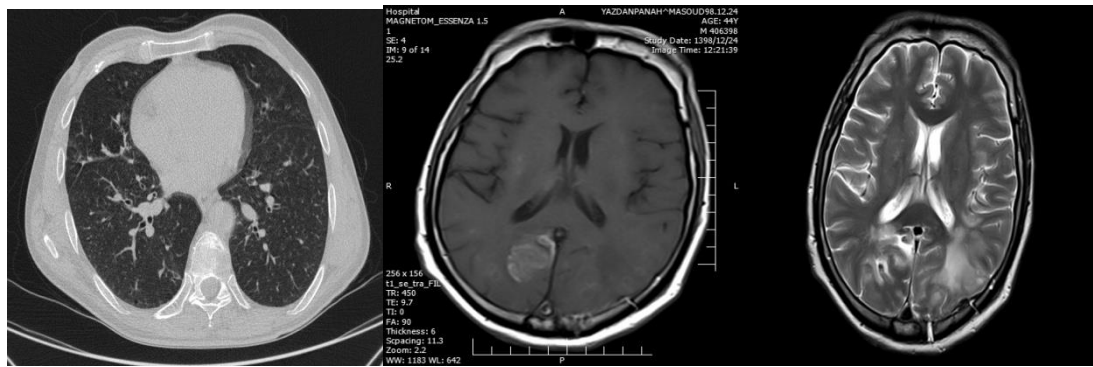
nuclear debris, few foamy histiocytes, rare hemosiderophages, and focal hemorrhage. The surrounding brain tissue showed edema, mild atypia of glial and astrocytic cells, granulation tissue-like angioblastic, and fibroblastic activity. The macroscopic view of lesions was a creamy light brownish tissue with a soft consistency (Figure 4).



**Figure 4.** Necrosis of brain tissue and neutrophil infiltration (magnification  $\times 100$ ); Granulation tissue formation around necrotic areas (magnification  $\times 100$ ).

After the neurosurgical biopsy of intracranial lesions and receiving various antibiotics for eight weeks, his headache and fatigue got much better, and he was discharged from the hospital (Figure 5). The study was approved by the Ethics

Committee of Rafsanjan University of Medical Sciences (Ethical code: IR.RUMS.REC.1399.131), following Helsinki Criteria.



**Figure 5.** Chest CT scan and brain MRI after treatment indicating complete resolution of lung abscess and significant resolution of brain lesions.

## Discussion

A brain abscess is a pus collection with a vascular capsule that primarily presents as cerebritis. Generally, the source of brain abscess can be any of the following: direct implant (e.g. neurosurgical complications), contiguous infection (e.g. sinusitis), hematogenous spread, and peripheral nerves (1). In 33% of cases, brain abscess is spread hematogenously, mostly with endocarditis (13%), pulmonary infection (8%), or dental infection (5%). Other cases are attributed to recent neurosurgery (9%) and cranial trauma (14%) (2). Lungs are an important source causing the hematogenous spread to the brain. Pulmonary abscess and empyema, especially in bronchiectasis cases, could cause BA, which may be in multiple cranial sites and mostly is passed through the middle cerebral artery at the gray-white matter junction. In addition, there are other sites of infection such as skin, pelvic, heart (endocarditis), and intra-abdomen (6).

The presentation includes diverse symptoms such as headache, fever, nausea, vomiting and focal neurologic symptoms, lethargy, seizure, the third and sixth cranial nerve deficits, and rapid headache, which may be due to the abscess rupture. Furthermore, BA could cause intracranial hypertension. Clinical presentation depends on the amount, size, location, and surrounding area of abscesses such as cisterns, ventricles, and the dural venous sinus. For instance, rupturing an abscess into the ventricle may cause ependymitis, ventriculitis, or even septic thromboembolism, leading to transverse or sigmoid sinus occlusion, brain edema, seizure, and raised intracranial pressure (6-8). Clinical manifestation of the brain abscess is non-specific in some cases; therefore, it may be diagnosed at late stages, so it leads to a poor prognosis (5).

In a contrast-enhanced CT scan at the early stages of abscess formation in which cerebritis occurs, an irregular low-density area is not enhanced or has partially patchy enhancement. Then, when the vascular capsule is formed, there is a regular enhancement in the border with 1-3 mm thickness (6). The MRI feature of pyogenic abscesses is that the central area of liquefaction has high signals, and the surrounding edematous brain tissue gives low signals on T1-weighted images. On T2-weighted images, the necrosis exhibits higher signals similar to the grey matter. Most abscesses have a rim, which is formed probably of the collagen and by the inflammation due to the free radicals and microhemorrhages in the abscess wall. The site of inflammation in tuberculous abscesses is significantly larger than that in pyogenic abscesses in the morphometric analysis of histologic sections (5).

Neurocysticercosis, which appears as a starry sky on brain imaging and manifests as tuberculoma, is a pathologic condition that may cause clinical features like multiple ring-enhancement lesions in the brain; as occurred in our case (9). Some conditions such as lymphoma, metastasis, pyogenic abscess, glioma, cryptococcosis and toxoplasmosis (in immunosuppression cases), sarcoidosis, larva migrans, and cryptic arteriovenous malformation (AVM) are among the uncommon causes of the ring-enhancing MRI lesions. Furthermore, the antibody-associated disease of myelin oligodendrocyte glycoprotein (MOG) can present itself by alexia, agraphia, aphasia, acalculia, right hemiplegia, and left-right disorientation (10).

Suzuki *et al.* in their study reported that a solitary and homogeneously enhancing mass masquerading as a malignant lymphoma that evolved into multiple hemorrhagic and necrotic



lesions has rarely been reported in granulomatous amoebic encephalitis (11). Toxoplasmosis is a protozoal infection-causing intracranial mass lesion (single or multiple) shown as ring-enhancing lesions on CT and MRI images, especially in immune-deficient patients (12). Moreover, Straehley et al. found multifocal ring-enhancing lesions on MRI in the basal ganglia, hypothalamus, thalamus, and internal capsule in a 44-year-old Caucasian male admitted to the hospital for left upper extremity paresthesia, gait instability, and painful vesicular skin caused by toxoplasmosis and HSV (13).

Our patient was an interesting case since he had no underlying disease and was taking no immunosuppressive drug. He was not old enough to be predisposed to geriatrics infectious diseases. Signs and symptoms of hospital arrival time like miotic pupils and bradycardia were probably owing to methadone toxicity. After diminishing methadone toxicity, signs and symptoms were purely in favor of neurological diseases, and MRI was more useful in diagnosis than CT scan. Thus, it was hypothesized that methadone toxicity followed by a confusional state for a prolonged period was the cause of aspiration of oral contents. As *peptostreptococcus* and some *anaerobe* bacteria

are the dominant flora of the mouth, they should have been the source of his lung abscess. An interesting point about the case was that he did not have lung abscess signs and symptoms except mild crackles at the lower lobes of his lungs. Accordingly, it is supposed that all these findings are consistent with each other.

The other important point of this case, which may reveal itself in other such patients, is that altered mental states like seizure, stroke, brain tumors, metastasis, other metabolic diseases, and drug effects with lowering the level of consciousness can lead to dysphagia. There should be concerns about aspiration and further complications, which may lead to aspiration pneumonia and hematogenous spread of infection to the brain, even in a patient without underlying diseases.

#### Acknowledgments

The authors would like to thank the Clinical Research Development Unit of Ali Ibn Abitaleb hospital, Rafsanjan University of Medical Sciences for its support and collaboration.

#### Conflict of interests

The authors declare that there is no conflict of interest.

#### References

1. Kragha KO. Multiple Brain Abscesses due to *Streptococcus anginosus*: Prediction of Mortality by an Imaging Severity Index Score. *Case Rep Radiol.* 2016; 2016: 7040352. doi: 10.1155/2016/7040352.
2. Sonnevile R, Ruimy R, Benzonana N, Riffaud L, Carsin A, Tadié JM, et al. ESCMID Study Group for Infectious Diseases of the Brain (ESGIB). An update on bacterial brain abscess in immunocompetent patients. *Clin Microbiol Infect.* 2017; 23(9): 614-20. doi: 10.1016/j.cmi.2017.05.004.
3. Brouwer MC, Coutinho JM, van de Beek D. Clinical characteristics and outcome of brain abscess: systematic review and meta-analysis. *Neurology.* 2014; 82(9): 806-13. doi: 10.1212/WNL.000000000000172.
4. Lakshmi V, Umabala P, Anuradha K, Padmaja K, Padmasree C, Rajesh A, et al. Microbiological spectrum of brain abscess at a tertiary care hospital in South India: 24-year data and review. *Patholog Res Int.* 2011; 2011: 583139. doi: 10.4061/2011/583139.
5. Muzumdar D, Jhawar S, Goel A. Brain abscess: an overview. *Int J Surg.* 2011; 9(2):136-44. doi: 10.1016/j.ijisu.2010.11.005.
6. Bokhari MR, Mesfin FB. Brain Abscess. 2021 Sep 15. In: StatPearls [Internet]. Treasure Island (FL): StatPearls Publishing ;2022. PMID: 28722871.
7. Patel K, Clifford DB. Bacterial brain abscess. *Neurohospitalist.* 2014; 4(4):196-204. doi: 10.1177/1941874414540684.
8. Ribeiro R, Patrício C, Valejo Coelho MM, Brotas V. A cerebral abscess at first internist glance. *BMJ Case Rep.* 2015; 2015: bcr2015212162. doi: 10.1136/bcr-2015-212162.
9. Ahmad R. Neurocysticercosis and starry sky appearance on brain imaging. *QJM.* 2020; 113(4): 283. doi: 10.1093/qjmed/hcz185.
10. Ataka T, Kimura N, Matsubara E. A case of myelin oligodendrocyte glycoprotein-antibody-

- associated disease presenting with tumefactive demyelinating lesion. *Mult Scler Relat Disord.* 2020; 43:102191. doi: 10.1016/j.msard.2020.102191.
11. Suzuki T, Okamoto K, Genaki N. A Homogeneously enhancing mass evolving into multiple hemorrhagic and necrotic lesions in amoebic encephalitis with necrotizing vasculitis. *Clin Imaging.* 2020; 60(1):48-52. doi: 10.1016/j.clinimag.2019.10.015.
  12. Lee GT, Antelo F, Mlikotic AA. Best cases from the AFIP: cerebral toxoplasmosis. *Radiographics.* 2009; 29(4): 1200-5. doi: 10.1148/rg.294085205.
  13. Straehley I, Varada N, Prokop I, Muxen C. Horner Syndrome induced by toxoplasmosis infection in a patient with AIDS and disseminated herpes simplex virus. *Am J Ophthalmol Case Rep.* 2020; 18: 100679. doi: 10.1016/j.ajoc.2020.100679.