

Corneal Ectasia after Photorefractive Keratectomy

Hamid Khakshoor¹, Hamid Gharaei¹, Malihe Nikandish^{2*}

1. Eye Research Center, Khatam-al-Anbia Eye Hospital, Mashhad University of Medical Sciences, Mashhad, Iran

2. Ophthalmology Department, Razi Hospital, Birjand University of Medical Sciences, Birjand, Iran



ABSTRACT

Two cases are presented with corneal ectasia after photorefractive keratectomy (PRK). Case 1 is a 24-year-old man with manifest refractions of -6.0 DS, -3.0 DC, axis 180° in the right eye and -4.50 DS, -4.0 DC, axis 160° in the left eye respectively with a symmetric bow-tie pattern bilaterally, without any evidence of keratoconus on corneal topography preoperatively. Ectasia occurred 10 months after surgery in the right eye.

Case 2 is a 20-year-old man with an attempted correction of -6.25 DS, -2.25 DC, axis 30° in the right eye, and -6.25 DS, -2.25 DC, axis 150° in the left eye. Thinnest central corneal thickness was 498µm and 499µm in the right and left eyes, respectively. Total ablation depth was 137 µm in the right eye and 136 µm in the left eye. 38 months after surgery ectasia developed in the left eye. Two patients had no family history suspicious for keratoconus.

Copyright: 2021 The Author(s); Published by Kerman University of Medical Sciences. This is an open-access article distributed under the terms of the Creative Commons Attribution License (<http://creativecommons.org/licenses/by/4.0>), which permits unrestricted use, distribution, and reproduction in any medium, provided the original work is properly cited.

Keywords: Cornea, Ectasia, Photorefractive keratectomy, Complication

Citation: Khakshoor H, Gharaei H, Nikandish M. Corneal ectasia after photorefractive keratectomy. Journal of Kerman University of Medical Sciences 2022; 29(1): 84-90. doi: 10.22062/jkmu.2022.91867

Received: 23.04. 2021

Accepted: 27.09. 2021

***Correspondence:** Malihe Nikandish; Email: nikandishm@bums.ac.ir

Published by Kerman University of Medical Sciences

Introduction

Corneal ectasia is characterized by progressive corneal thinning associated with loss of uncorrected visual acuity (UCVA) and often best spectacle-corrected visual acuity (BCVA) (1).

The estimated incidence of ectasia after LASIK ranges from 0.04% to 0.6%. Recognized risk factors for ectasia include corneal ectatic disorders, specific topographic patterns (forme fruste keratoconus), low residual stromal bed thickness, young age, low preoperative corneal thickness, and high myopia (2).

Ectasia may also occur after PRK in eyes with known risk factors such as inferior topographical steepening and in eyes without definite risk factors (3).

A study from Emory University, a tertiary referral center, showed that the incidence of ectasia following LASIK was 36 times higher than the incidence of ectasia after PRK (4).

In this case report, 2 cases of ectasia after PRK are described and the possible risk factors for this complication are discussed.

Case reports

Case 1

A 24-year-old man underwent refractive surgery for myopic astigmatism in both eyes in December 2010. Family history for keratoconus was negative. The BCVA was 20/40 with manifest refraction of -6.0 DS, -3 DC, axis 180° in the right eye, and 20/20 with manifest refraction of -4.50 DS, -4 DC, axis 160° in the left eye. The right eye of this case was amblyopic. The patient had a stable refraction for at least two years. No clinical signs of keratoconus were found under slit-lamp examination. Preoperative central corneal pachymetry was 518 μ m in the right eye and 536 μ m in the left eye. Preoperative corneal topographies (EyeSys Corneal Analysis System 2000, Eye Sys Laboratories, Houston, TX) exhibited a symmetric bow-tie pattern bilaterally, with Sim-K values of 44.11/41.7 in the right eye and 44.70/41.41 in the left eye (Figure 1). Preoperative orbiscan plots are also shown in Figure 2.

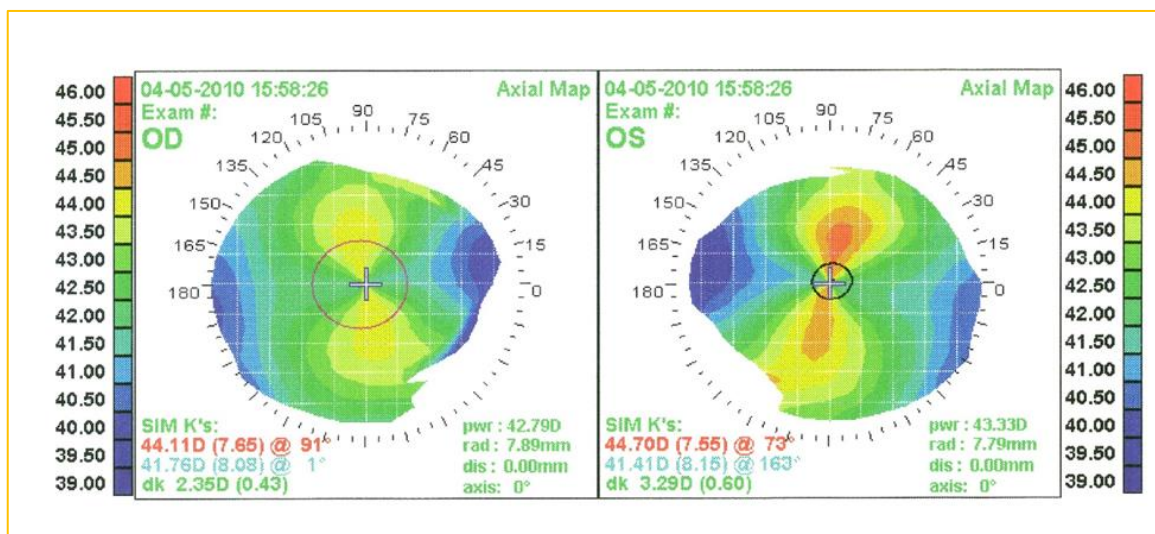


Figure 1. A: Case 1, right eye. Preoperative topography showing symmetric bow-tie with a central K-reading of 42.79 D; B: Case 1, left eye. Preoperative topography also showing symmetric bow-tie with a central K-reading of 43.33 D

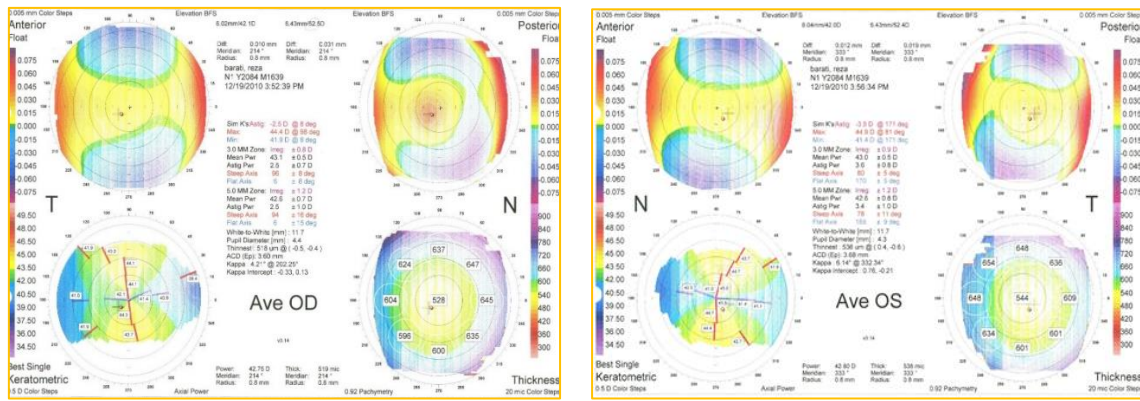


Figure 2. A: Case 1, right eye preoperative orbscan B: Case 1, left eye preoperative orbscan.

Bilateral PRK was performed using an excimer laser (Keracor Technolas 217 z-V4.21, Bausch & Lomb Surgical, Claremont, CA) with tissue saving mode. The ablation zone diameter was 6 mm in both eyes. Total ablation depth was 114 μm in the right eye and 109 μm in the left eye. The early postoperative course was uneventful. Three months after surgery,

uncorrected visual acuity was 20/40 in the right eye and 20/20 in the left eye. Ten months after surgery, the patient referred with -11 DS, -2.00 DC, axis 90° the in right eye and -0.5 DS, -0.5 DC, axis 120° in the left eye. The BCVA was 20/200 in the right eye and 20/20 in the left eye. Postoperative orbscan and topography plots are shown in Figure 3.

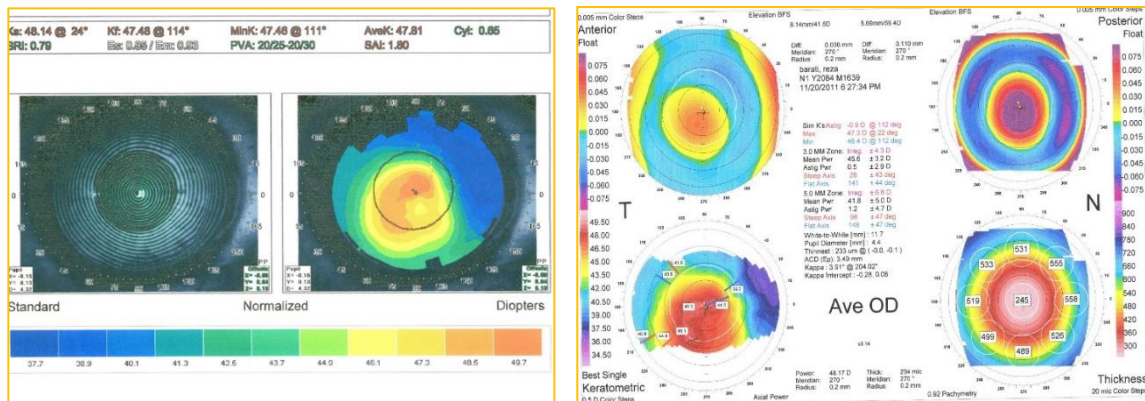


Figure 3. A: Case 1, right eye 21 months' postoperative topography; B: Case 1, right eye postoperative orbscan show prominent corneal ectasia.

Case 2

A 20-year-old man was undergone bilateral PRK for myopic astigmatism with an attempted correction of -6.25 DS, -2.25 DC, axis 30° in the right eye, and -6.25 DS, -2.25 DC, axis 150° in the left eye. The BCVA was 20/50 in both eyes. Only preoperative orbscan was available which is shown in Figure 4. Axial map exhibits a symmetric bow-tie pattern. The thinnest central corneal thickness readings measured by orbscan were 498 μm in the right eye and 499 μm in the left eye. Bilateral PRK was performed with an excimer laser (Keracor Technolas 217 z-V4.21,

Bausch & Lomb Surgical, Claremont, CA). The ablation zone diameter was 5.7 mm in both eyes. Total ablation depth was 137 μm in the right eye and 136 μm in the left eye. Two months after the treatment, the uncorrected visual acuity (UCVA) was 20/50 in both eyes. Thirty-eight months after the surgery, the UCVA was 20/50 in the right eye and 20/120 in the left eye with manifest refractions of -0.5 DS, -0.5 DC, axis 53° and -0.5 DS, -2.5 DC, axis 110°, respectively. Topography maps revealed an inferior steepening suggestive of early corneal ectasia (Figure 5).

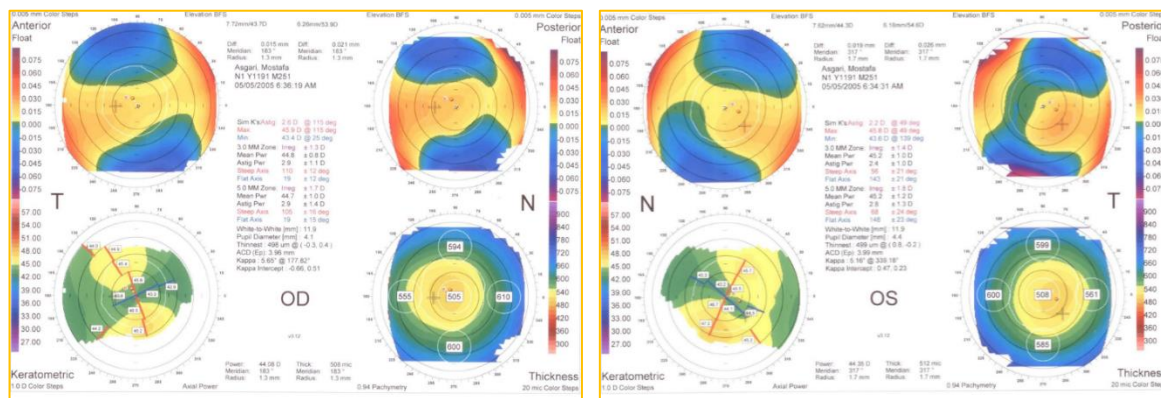


Figure 4. A: Case 2, right eye preoperative orbscan; B: Case 2, left eye preoperative orbscan

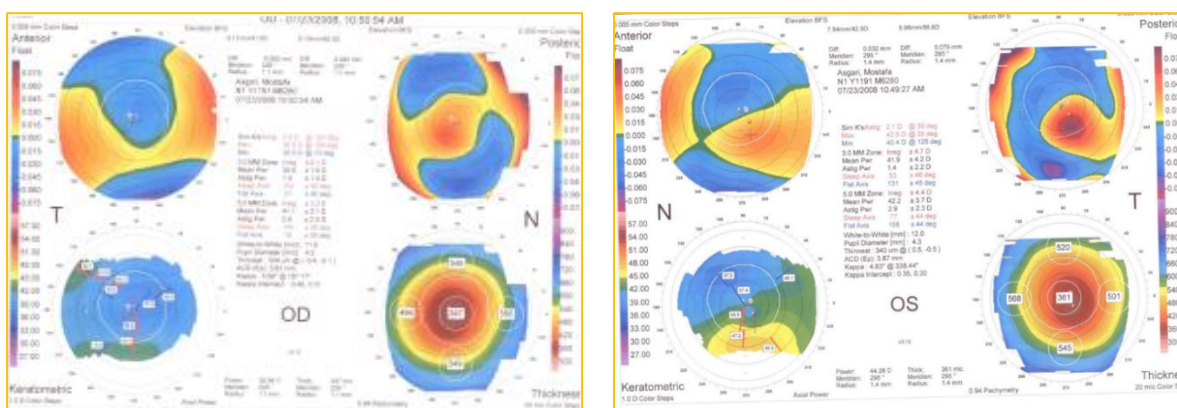


Figure 5. A: Case 2, right eye postoperative orbscan; B: Case 2, left eye postoperative orbscan with inferotemporal corneal ectasia

Discussion

The first cases of corneal ectasia as a serious complication of refractive surgery were reported by Seiler *et al.*, in three eyes that had laser in situ keratomileusis (LASIK) for myopia from -10.00 to -13.50 D. After the above-mentioned study, the literature review showed some post-PRK and post-LASIK ectasia that are discussed here (5).

Most surgeons predominantly favor PRK technique for thin and high-risk corneas. A global literature review by McDonald (2011) revealed only 32 reported cases of ectasia occurring after surface ablation, however, the number of cases has increased over the last 3 years, possibly because of the occurrence of very late onset of ectasia after PRK (4).

Malecaze *et al.* reported the first case of bilateral corneal ectasia four years after PRK in a patient with low-degree myopia. In a 22-year-old man, BCVA was 20/20 with -1.5 DS, -1.00 DC, axis 105° and -1.5 DS, -1.00 DC, axis 6°, in the right and left eyes, respectively. The patient had a stable refraction for 4 years. Preoperative ultrasonic central corneal pachymetry was 495

µm. Central keratometry measured was 43.77/43.32 in the right eye and 43.88/43.26 in the left eye. The ablation zone diameters were 5.5 and 5.3 mm in the right and left eyes, respectively, with a peripheral treatment zone from 6 to 8.5 mm. In addition, the calculated total ablation depth was 32 µm in the right eye and 30 µm in the left eye. Therefore, the residual thickness was more than 460 µm in both eyes. The early postoperative course was uneventful. Retrospective analysis of preoperative videokeratography indicated the existence of forme fruste keratoconus characterized by clinical and topographical signs of keratoconus in the left eye and a typical topographical keratoconus pattern in the right eye. The onset of corneal ectasia in their case was four years after surgery (6).

In another study, Parmar *et al.*, reported a case of posterior keratectasia followed over a period of 6.5 years after unilateral repeated myopic PRK. The attempted correction was -9.75 DS. A further PRK was performed one year later due to the corneal haze and regression with

a target correction of -4.5 DS and a 6-mm ablation zone. The patient was 47-year-old at the time of surgery with no clinical evidence of corneal ectasia (keratoconus) preoperatively. It should be noted that although corneal topography and pachymetry maps were unavailable, however, the left cornea was topographically normal, with a central corneal thickness of 620 μm and no evidence of keratectasia. The case had repeated deep ablation (7).

Holland *et al.*, reported five patients who developed ectasia after PRK. However, two patients had hyperopic astigmatism; four patients had multiple retreatments resulting in corneal perforation, or were diagnosed as keratoconus suspects preoperatively, although no topographies were published (8).

Hyojin *et al.*, reported prominent post-PRK ectasia of the cornea in a 42-year-old patient. Preoperative pachymetry was 536 μm with an intended ablation of 74 μm . Preoperative refraction was -7.25 DS, -0.50 DC, axis 12° with a best spectacle-corrected visual acuity (BSCVA) of 20/20 in both eyes. Keratometry results were 43.75/43.50 D and 43.00/42.75 D in the right and left eyes, respectively. Corneal topography was not performed. The surgical equipment used was a Summit excimer laser. The procedure was uneventful. Nine years after surgery, prominent ectasia occurred in the left eye (9).

Leccisott *et al.*, reported four patients of corneal ectasia after PRK in a retrospective, non-comparative case series including 6453 cases of myopic PRK with a minimum follow-up of 18 months (10).

The first case was a 38-year-old woman that presented with bilateral ectasia 3 years after surgery with attempted correction of -7.00 DS, -3.00 DC, axis 180° in the right eye, and -6.00 DS, -4.00 DC, axis 180° in the left eye, with preoperative US pachymetry results of 520 and 510 μm in the right and left eyes, respectively. Maximum curvature was 44.3 D in the right eye and 45.5 in the left eye. Preoperative axial videokeratography showed forme fruste keratoconus in both eyes. The presumed optical zone and ablation depth are unknown. Bilateral inferotemporal ectasia was shown three years after surgery.

The second case was a 31-year-old man, with attempted correction of -4.5 DS, -1.75 DC, axis 175°, a BSCVA of 1.0, an US central pachymetry of 487 μm , and an axial

videokeratography showing a regular bow-tie pattern, with a maximum curvature of 45.75 D in the right eye. The patient was undergone penetrating keratoplasty for keratoconus in the fellow eye. Corneal ectasia occurred 13 months after surgery.

The third patient was a 31-year-old man with preoperative refraction of -3.75 DS, -0.75 DC, axis 10° and -3.75 DS, -0.5 DC, axis 150° in the right and left eyes, respectively, and a bilateral 1.0 BSCVA. In a preoperative corneal topography, only aberration index is abnormal and no keratoconus is indicated by the videokeratographer expert system. Three years after surgery, corneal ectasia occurred in the left eye. The fourth patient was a 38-year-old woman with preoperative refraction of -2.5 DS, -0.75 DC, axis 130° in the right eye and -1.5 DS, -1.25 DC, axis 130° in the left eye, and a bilateral BSCVA of 1.0. Ultrasound central pachymetry results were 510 and 509 μm , in the right and left eyes, respectively. Corneal topography showed a moderate inferior steepening, with a maximum curvature of 48.3 D and an abnormal vertical asymmetry index in the left eye. The keratoconus was considered 'possible' by the keratograph expert system in the left eye. Ablation depth of 50 μm was planned. Six months later, corneal ectasia was observed in the left eye (10).

Mortensen (2012) reported a case of post-PRK ectasia 16 years after surgery that attempted for correction of -3.5 D myopia in both eyes. The patient was a 21-year-old male at the time of surgery. Postoperative pachymetry results were 424 and 440 μm in the right and left eyes, respectively, in spite of CXL progression that continued (11).

Randleman *et al.*, reported two patients who developed bilateral corneal ectasia after PRK. The first case was a 37-year-old man with manifest refractions of -4.00 DS, 2.50 DC, axis 160° (20/20) in the right eye and -7.00 DS, -3.00 DC, axis 180° (20/30) in the left eye. The patient had thin corneas (472 and 441 μm , respectively); and an inferior paracentral steepening in the right eye and central steepening in the left eye on topography. The planned ablation depths were 53 μm in the right eye and 100 μm in the left eye. Three weeks after PRK, ectasia was observed bilaterally (3).

The second case was a 40-year-old man with manifest refraction of -8.50 DS, +3.75 DC, axis 123° in the right eye and -9.25 DS, +4.00 DC, axis 77° in the left eye. The corneal thickness of

509 and 508 μm were noted respectively. Preoperative topography exhibited a symmetric bow-tie pattern bilaterally, with Sim-K values of 46.68/43.21 D in the right eye and 46.80/43.38 D in the left eye. The patient had a family history suspicious for keratoconus, with a sibling who had bilateral corneal transplantation at a young age. Planned central ablation depth was 98 μm in the right eye and 106 μm in the left eye. Ten months after surgery, topography revealed an inferonasal steepening suggestive of early bilateral corneal ectasia (3).

Hashemian *et al.* reported a post-PRK ectasia in a 24-year-old man without any obvious preoperative risk factor that presented four years after surgery. Preoperative manifest refraction was -2.75 DS in both eyes. Pachymetry was 527 μm in the right eye and 554 μm in the left eye. Ablation depth was 49.7 and 39.7 μm , respectively. All topography indices were normal in both eyes and KpI was 0% bilaterally (12).

According to McDonald and Marguerite, "The onset of post-PRK ectasia is so late that it is possible to miss the diagnosis." They also stated that "For example, increased myopia can be mistaken for cataractous changes" (4).

In the literature review, it was revealed that post-PRK ectasia can occur in an individual with an age of 47 years at the time of surgery (7). Literature review also outlines that the onset time of post-PRK ectasia varies from 6 months (10) to 16 years (11) after surgery. Corneal ectasia can develop in patients with known risk factors and without any known risk factors.

One of the cases (case 1) in the present report had a symmetric bow-tie topographic pattern bilaterally and a relative deep ablation without

any obvious risk factor. Ectasia was observed 10 months after operation.

The second case had preoperative suspicious findings including young age, thin corneas, and BSCVA less than 20/20. But in imaging maps, he had a symmetric bow-tie topographic pattern bilaterally characterized by some degree of enantiomorphism. This patient had deep ablation with low residual stromal thickness bilaterally. In this case, ectasia occurred 38 months after surgery. In our cases, the onset of ectasia was not too late in comparison with post-LASIK ectasia.

In conclusion, corneal ectasia can occur after PRK, especially in susceptible individuals. To minimize the risk of postoperative corneal ectasia, PRK should be performed only if the corneal topography is normal. The safety of the PRK procedure must be evaluated in patients with pathological corneas. Extensive patient counseling and extreme caution should be used in these patients.

Acknowledgments

Special thanks to the patients for giving us the permission to report their illness.

Authors' contributions

All authors contributed to the study's conception and design, Material preparation and data collection.

Funding

Non

Conflict of interest

The authors declare that there is no conflict of interests.

References

- Randleman JB, Russell B, Ward MA, Thompson KP, Stulting RD. Risk factors and prognosis for corneal ectasia after LASIK. *Ophthalmology*. 2003; 110(2):267-75. doi: 10.1016/S0161-6420(02)01727-X.
- Randleman JB, Stulting RD. Corneal ectasia. In Alio y Sanz JL, Azar DT. editors. *Management of complications in refractive surgery*. New York, NY: Springer 2008.
- Randleman JB, Caster AI, Banning CS, Stulting RD. m. *J Cataract Refract Surg*. 2006; 32(8):1395-8. doi: 10.1016/j.jcrs.2006.02.078.
- Marguerite B. McDonald, MD. Surgeon: LASIK involves far greater risk of postop ectasia than does PRK. 10 January 2011. Available from: <https://www.healio.com/news/ophthalmology/20120331/surgeon-lasik-involves-far-greater-risk-of-postop-ectasia-than-does-prk>.
- Seiler T, Koufala K, Richter G. Iatrogenic keratectasia after laser in situ keratomileusis. *J Refract Surg*. 1998;14(3):312-7. PMID: 9641422.
- Malecaze F, Couillet J, Calvas P, Fournié P, Arné JL, Brodaty C. Corneal ectasia after photorefractive keratectomy for low myopia. *Ophthalmology*. 2006; 113(5):742-6. doi: 10.1016/j.ophtha.2005.11.023.

7. Parmar D, Claoué C. Keratectasia following excimer laser photorefractive keratectomy. *Acta Ophthalmol Scand.* 2004; 82(1):102-5. doi: 10.1111/j.1395-3907.2003.0189b.x.
8. Holland SP, Srivannaboon S, Reinstein DZ. Avoiding serious corneal complications of laser assisted in situ keratomileusis and photorefractive keratectomy. *Ophthalmology.* 2000; 107(4):640-52. doi: 10.1016/s0161-6420(99)00131-1.
9. Kim H, Choi JS, Joo CK. Corneal ectasia after PRK: clinicopathologic case report. *Cornea.* 2006; 25(7):845-8. doi: 10.1097/01.icc.0000224634.72309.43.
10. Leccisotti A. Corneal ectasia after photorefractive keratectomy. *Graefes Arch Clin Exp Ophthalmol.* 2007; 245(6):869-75. doi: 10.1007/s00417-006-0507-z.
11. Mortensen JN. Corneal ectasia after PRK. *Int J Keratoco Ectatic Corneal Dis.* 2012;1(1):73-74. doi: 10.5005/jp-journals-10025-1014.
12. Hashemian MN, Alizadeh M, Hashemi H, Rahimi F, Management of unpredictable post-PRK corneal ectasia with intacs implantation. *Iranian Journal of Ophthalmology* 2009; 21(3):63-70.