

Evaluation of the Results of Using Silicone Membrane between Muscle and Dura after Craniotomy in Patients Requiring Delayed Bone Replacement at the Craniotomy Site: A Prospective Cohort Trial

Saied Abrishamkar¹, Mehdi Shafiei², Mehdi Mahmoodkhani¹, Ghasem Yadegarfar², Kamran Kaghazchi^{1*}, Donya Sheibani Tehrani³

1. Department of Neurosurgery, Isfahan University of Medical School, Isfahan, Iran

2. Department of Epidemiology and Biostatistics, School of Health, Isfahan University of Medical School, Isfahan, Iran

3. Department of Information Technology, Shahid Beheshti University, Tehran, Iran



ABSTRACT

Background: The adhesion between the dura and the muscle is one of the serious problems of patients who need delayed cranial bone replacement due to decompressive craniotomy after brain swelling, but there is no ideal solution to reduce this complication. This study aimed to determine the effect of implanting a silicone membrane between the muscle and the dura after craniotomy surgery in patients requiring delayed bone replacement at the craniotomy site.

Methods: In this clinical prospective cohort trial study with no evidence, all patients undergoing late cranial bone grafting after craniotomy were selected, and a total of 24 people were included in this study. During the craniotomy, a silicone mesh measuring 5 × 5 cm was placed between the dura and the muscle. Adhesion between the dura and the muscle and side effects associated with this procedure were examined during cranial bone grafting.

Results: Out of 24 patients requiring delayed cranial bone grafting, three individuals died and six individuals did not refer for cranioplasty; therefore, the operation was performed on 15 patients. During the operation, no cases of muscle-dura adhesion were observed, and in all 15 patients, the dura was completely detached from the muscle. Also, none of the patients presented side effects such as muscle bleeding at the surgery site, infection, and allergy to the mesh.

Discussion: Implantation of silicone layer between the dura and the muscle during craniotomy in patients suffering from cerebral edema can prevent muscle-dura adhesion without causing serious complications for the patients.

Keywords: Cerebral edema, Craniotomy, Cranioplasty, Adhesion

Citation: Abrishamkar S, Shafiei M, Mahmoodkhani M, Yadegarfar Gh, Kaghazchi K, Sheibani Tehrani D. Evaluation of the results of using silicone membrane between muscle and dura after craniotomy in patients requiring delayed bone replacement at the craniotomy site: A prospective cohort trial. Journal of Kerman University of Medical Sciences 2022; 29(3): 307-312. doi: 10.22062/JKMU.2022.91957

Received: 24. 08. 2021

Accepted: 27. 11. 2021

***Correspondence:** Kamran Kaghazchi; Email: kaghazchi1356@gmail.com

Published by Kerman University of Medical Sciences

Introduction

Decompressive craniotomy is one of the most common practices in neurosurgery that has increased with the increase in urbanization, machine life, the age of communities, as well as the increase of traumas caused by motor vehicle accidents in developing societies (1). Iran has not been an exception to this rule, and unfortunately, with the great number of road traffic accidents and the traumas caused by them, as well as the increasing prevalence of diseases caused by inactivity in the young and middle-aged population, the need for decompressive craniotomy after ischemic stroke and acute subdural is also raising (2,3).

In some neurosurgery patients who need emergency or elective craniotomy, some conditions may be created during the operation that lead to loss of autoregulation and brain swelling (4), and at the end of the surgery to maintain normal intracranial pressure (ICP), there will be no possibility to reposition the removed free bone flap (5). In such cases, bone replacement is recommended after about three weeks to six months (6). The problem is that in such cases, during this period of time, muscle and fascia at the craniotomy site become strongly attached to the dura and lead to some complications, including pain and difficulties during the operation (7).

The use of silicone mesh at the site of surgery in these patients is one of the proceeding actions that seems to reduce the adhesion between the muscle and the dura and facilitate the cranioplasty (8). Also, by using this simple and low-cost procedure, not only these complications are prevented, but also, the process can be turned into a comprehensive method with acceptable results. Therefore, this study aimed to evaluate the results of using silicone membranes in the space between the muscle and the dura after craniotomy in patients requiring delayed bone placement at the craniotomy site.

Materials and Methods

This prospective cohort study with historical evidence approved by the Ethics Committee of Isfahan University of Medical Sciences (Ethical code: IR.MUI.REC.1396.3.643) was conducted during the years 2018 to 2020 at Ayatollah Kashani hospital in Isfahan. The study population included the patients undergoing craniotomy with delayed cranial bone placement at the craniotomy site.

In this prospective cohort study, the comparison is between patients included in the study whom silicone mesh was used for, versus patients who were not included in this study and routinely underwent cranioplasty after three weeks to six months without using mesh.

The inclusion criteria were undergoing decompressive craniotomy surgery, being a candidate for implantation of silicone membrane between muscle and dura, having no underlying diseases including diabetes, and filling the informed consent by patient or companions confirming the participation in the study. Patients who died during the craniotomy operation before the bone implantation or did not return for the cranioplasty operation were excluded from the study.

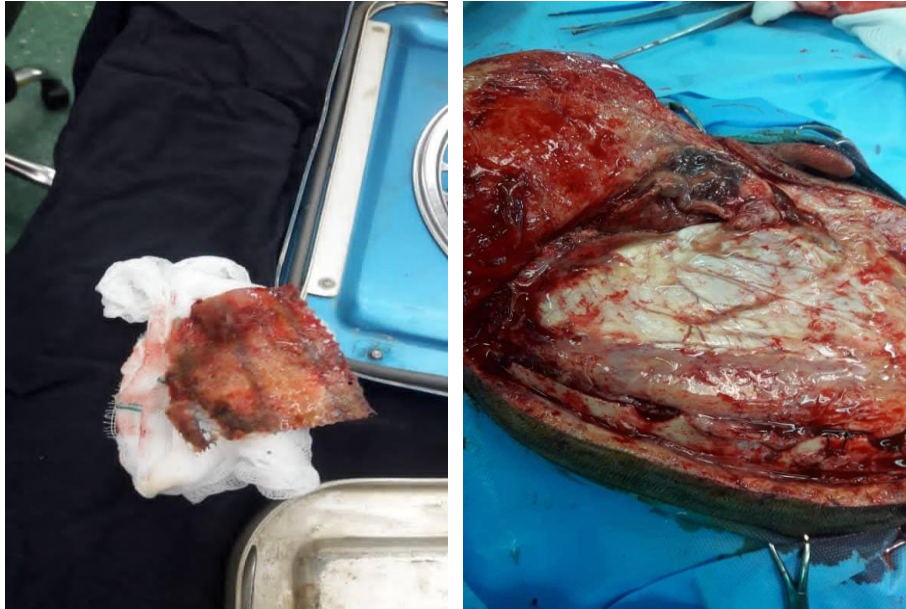The data associated with muscle-dura adhesions, dural rupture, muscle bleeding during surgery, and postoperative pain intensity in conscious patients, were recorded and evaluated as the findings of the study. The amount of bleeding during the operation was determined based on the number of gauzes impregnated with blood (the volume of each gauze was 10 cc). Pain intensity was evaluated using VAS scale between zero to ten. Other complications such as infection and pruritus were also evaluated and recorded, as well as the repair site condition. This study was performed using a census method and all patients requiring delayed cranial bone placement at the craniotomy site who underwent surgery in the Ayatollah Kashani hospital from the beginning of 2018 to the end of 2020 and were eligible to enter the study, were included in the study.

The method was so that from early 2018 to late 2020, all patients who suffered acute cerebral edema due to ischemic or subdural hematoma and needed decompressive craniotomy surgery were examined and checked; the patients who needed delayed bone replacement were included in the research.

The intervention process in these patients included the implantation of a silicone membrane between the muscle and the dura at the end of the operation (Figure 1 and 2). Depending on the degree of swelling, the time interval between craniotomy and cranioplasty ranged from six weeks to six months. Patients were followed up by telephone weekly during this period and the incidence of side effects such as infection and severity of postoperative pain (in conscious patients) were evaluated and recorded.

Figure 1-A shows a mesh removed from the space between the muscle and the dura that has no adhesion. Figure 1-B shows the site of the

cranioplasty, which shows neither bleeding from the muscle, nor adhesions between the muscle and the dura.



Figures 1 (A) and (B). Insertion of a silicone mesh between the dura and the muscle during craniotomy.

The obtained data were finally entered into SPSS version 26 and analyzed by Chi-square and t-test.

Results

From early 2018 to late 2020, a total of 24 patients were examined. They all underwent decompressive craniotomy requiring delayed bone replacement and had the conditions and consent to participate in this study. The mean age of the above-mentioned patients was 46.8 ± 16 years with a range of 22-78 years of whom 20

(83.3%) were male and four (16.7%) were female. The cause of cerebral edema in six patients (25%) was subarachnoid hemorrhage, in two patients (8.3%) was epidural hematoma, in four patients (16.7%) was intracerebral hemorrhage, in eight patients (33.3%) was subdural hematoma, and in four patients (16.7%) was stroke (Figure 2).

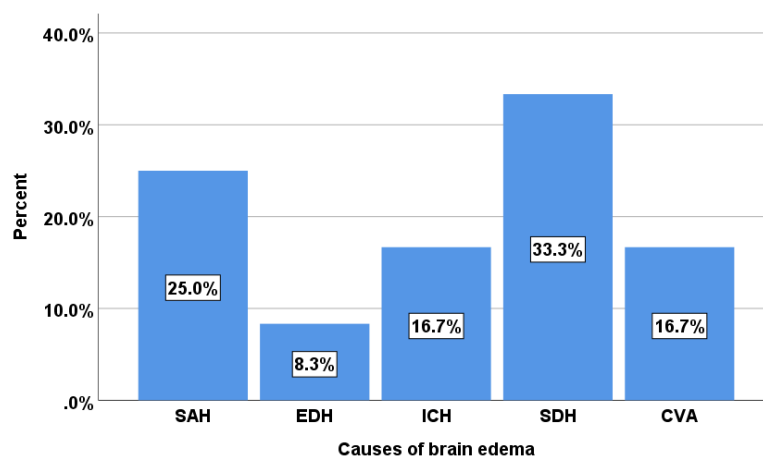


Figure 2. Frequency of the causes of cerebral edema in patients studied.

Table 1 shows the frequency distribution of the causes of cerebral edema in terms of age and gender of patients. According to this table, patients suffering from epidural hematoma had the highest mean age and those suffering from subarachnoid hemorrhage had the lowest one, but the mean age of patients did not differ significantly in terms of the cause of cerebral

edema ($P=0.052$). The most common cause of cerebral edema in men was subdural hematoma with a frequency of seven cases (35%) and in women, intracerebral hemorrhage with a frequency of two cases (50%); thus, the cause of cerebral edema was significantly different between two genders ($P=0.028$).

Table 1. Frequency distribution of the cause of cerebral edema in terms of age and sex

Cause of Cerebral Edema	Average age	Abundance of sex	
		Male	Female
Subarachnoid hemorrhage	36.83±14.6	6 (30)	0 (0)
Epidural hematoma	49±5.66	2 (10)	0 (0)
Intracerebral hemorrhage	66.25±10.78	2 (10)	2 (50)
Subdural hematoma	43.5±16.42	7 (35)	1 (25)
Stroke	46.79±10.63	3 (15)	1 (25)
P-value	0.052	0.028	

Out of 24 patients undergoing craniotomy who needed delayed placement of cranial bone, six patients (25%) did not refer for cranioplasty and three of them (12.5%) died; therefore, cranioplasty was performed with silicone meshes on 15 patients (62.5%). The mean time interval between craniotomy and cranioplasty was 9.93 ± 4.44 weeks. Muscle removal from dura was performed easily in all patients undergoing meshing and no case of adhesion was observed in any of them. There was also no case of active muscle bleeding in any patients. In one of the patients, two weeks after decompressive craniotomy, the incision was opened and the mesh was removed due to subcutaneous discharge on the posterior side of the incision, but the discharge site was not relevant to the location of the mesh. None of the patients undergoing meshing complained of severe postoperative pain and generalized pain during the time interval between craniotomy and cranioplasty.

Discussion

Muscle-dura adhesion between craniotomy and cranioplasty in patients with cerebral edema for whom cranial bone implantation is not possible during surgery is a serious problem, as this adhesion can lead to bleeding while separating the muscle from the dura, localized injury, and the incidence of surgical site infection as well as being annoying to the patients during the treatment period. Therefore, it seemed that the placement of a silicone mesh between the dura and the muscle could prevent the two tissues from sticking to each other during

the time interval between craniotomy and repositioning of the skull bone. Therefore, this study was performed to determine the results of the implantation of silicone membrane in the space between the muscle and rigid tissue after craniotomy surgery in patients requiring delayed bone placement at the craniotomy site.

The findings of this study showed that the implantation of a silicone membrane between the muscle and the dura prevents adhesion between these two tissues, and meshing in patients undergoing craniotomy who require delayed cranial bone placement appears to facilitate bone placement without causing serious side effects in the patients. In a study by Mumert *et al.*, the effects of using a Sefrafilm layer in preventing muscle-dura adhesion in three craniotomy patients were examined, and in all three patients, no adhesion was observed between the muscle and the dura during the placement of the skull bone. No side effects were observed in any patients (9). In another study by Zhou *et al.*, 56 patients underwent decompressive craniotomy using an anti-adhesive substance called COMPONT to prevent muscle-dura adhesion, two patients presented for cranioplasty, and no adhesion was observed during the operation. Also, none of the patients developed postoperative complications such as hematoma and infection (10). In another study by Bulters *et al.*, the effect of implanting a silicone layer between the dura and the muscle in 50 patients undergoing decompressive craniotomy was investigated. According to the findings of this study, no case of adhesion was

observed in any of the patients during cranioplasty (11).

The results of the present study showed that in patients undergoing craniotomy with the implantation of a silicone layer between the muscle and the dura, no serious complications such as infection and severe pain occurred, which is consistent with the findings of the previous studies (9-11). Therefore, it seems that the implantation of silicone mesh will improve the quality of cranioplasty in these patients.

Brain edema is defined as an increase in the fluid inside the brain and most often occurs in response to certain types of brain injuries including stroke, concussion, subarachnoid hemorrhage, primary and secondary malignancies, metabolic disorders, infection failure, and inflammation disorders (12). Cerebral edema is an acute problem that can occur suddenly and lead to severe boredom or death in patients with brain injury (13).

As the skull cannot expand its space, any increase in brain volume due to an increase in cerebrospinal fluid levels can quickly put pressure on vital structures in the central nervous system. If these conditions are ignored, the resulting swelling can lead to rapid death. Almost all organs of the body can be affected by increased intracranial pressure due to cerebral edema (13). Therefore, paying attention to

cerebral edema during cranioplasty is very important. Bleedings during the separation of the dura from the muscle and local tissue damage can exacerbate swelling at the surgical site. In a limited number of previous studies, a variety of materials and methods have been used to reduce muscle-dura adhesion. In general, the findings of these studies, including the present study, show that the use of silicone mesh in the mentioned patients is safe and can significantly prevent adhesions and improve the outcome of cranioplasty.

The main limitations of this study were the small sample size and the short follow-up period after cranioplasty. It is suggested to perform further studies in this respect. Another weakness of this study is the lack of access to the percentage of dural rupture during the separation of the muscle from the dura and the amount of muscle bleeding in patients who did not have mesh in their surgery.

Conclusion

The findings of this study showed that the implantation of a silicone layer between the dura and the muscle during craniotomy in patients with cerebral edema can prevent the dura-muscle adhesion without causing serious complications for the patients.

References

- Groombridge C, Maini A, Mathew J, O'Keeffe F, Noonan M, Smit V, et al. Decompressive craniotomy. *Emerg Med Australas.* 2020; 32(4):663-6. doi: 10.1111/1742-6723.13520.
- Khosravi MH. Disparity in discharging elderly traumatic brain injury patients to rehabilitation centers based on trauma center level. *Am J Surg.* 2020; 220(2):506. doi: 10.1016/j.amjsurg.2020.04.015.
- Fukuda Y, Matsuo A, Hirayama K, Sato K, Ozono K, Soejima K, et al. Two cases of late-onset brain edema after craniotomy for unruptured intracranial aneurysms suspected to be due to an allergic reaction to arachnoid plasty material. *No Shinkei Geka.* 2020; 48(3):213-21. Japanese. doi: 10.11477/mf.1436204165.
- Foley KT, Woodard EJ, Slotkin JR, Mayotte CK, Baldwin AC, Brown MC, et al. Cranial flap fixation in sheep using a resorbable bone adhesive. *J Neurosurg.* 2020:1-9. doi: 10.3171/2019.11.JNS192806.
- Yang HA, Sun SC, Zheng XR, Ding F, Bie YF. Effect of subdural muscle packing in repairing dura mater after retrosigmoid craniotomy. *J Int Med Res.* 2020; 48(3):300060520910299. doi: 10.1177/0300060520910299.
- Aldrich AL, Heim CE, Shi W, Fallet RW, Duan B, Kielian T. TLR2 and caspase-1 signaling are critical for bacterial containment but not clearance during craniotomy-associated biofilm infection. *J Neuroinflammation.* 2020; 17:114. doi: 10.1186/s12974-020-01793-6.
- Shay T, Belzberg M, Asemota AO, Mitchell KA, Wolff A, Santiago GF, Huang J, Brem H, Gordon CR. Risk of complications in primary versus revision-type cranioplasty. *J Craniofac Surg.* 2020; 31(2):423-27. doi: 10.1097/SCS.0000000000006134.

8. Kwiecien G, Sinclair N. Long-term Effect of Cranioplasty on Overlying Scalp Atrophy. *Plastic and Reconstructive Surgery*. 2020; 8(8): e3031. doi: 10.1097/GOX.0000000000003031
9. Mumert ML, Altay T, Couldwell WT. Technique for decompressive craniectomy using Sefrafilm as a dural substitute and anti-adhesion barrier. *J Clin Neurosci*. 2012; 19(3):455-7. doi: 10.1016/j.jocn.2011.09.004.
10. Zhou Y, Wang G, Liu J, Du Y, Wang L, Wang X. Application of COMPONT medical adhesive glue for tension-reduced duraplasty in decompressive craniotomy. *Med Sci Monit*. 2016; 22:3689-93. doi: 10.12659/MSM.896982.
11. Bulters D, Belli A. Placement of silicone sheeting at decompressive craniectomy to prevent adhesions at cranioplasty. *Br J Neurosurg*. 2010; 24(1):75-6. doi: 10.3109/02688690903506135.
12. Chughtai KA, Nemer OP, Kessler AT, Bhatt AA. Post-operative complications of craniotomy and craniectomy. *Emerg Radiol*. 2019; 26(1):99-107. doi: 10.1007/s10140-018-1647-2.
13. Jimenez-Martinez E, Cuervo G, Hornero A, Ciercoles P, Gabarros A, Cabellos C, et al. Risk factors for surgical site infection after craniotomy: A prospective cohort study. *Antimicrob Resist Infect Control*. 2019; 8:69. doi: 10.1186/s13756-019-0525-3.