

A Randomized Clinical Trial of Using Niosomal Zinc Sulfate Plus Cryotherapy in Comparison with Placebo Along with Cryotherapy in Treatment of Common Wart

Saeedeh Farajzadeh, M.D.¹, Abbas Pardakhti, Ph.D.², Saman Mohammadi, M.D.³, Fahameh Fadaei, M.D.⁴,
Maryam Khalili, M.D.³, Azadeh Mohebbi, M.D.³, Mahin Aflatoonian, M.D.⁵

1- Professor of dermatology, Leishmaniasis Research Center, Kerman University of Medical Sciences, Kerman, Iran

2- Professor, Department of Pharmaceutics, School of Pharmacy, Kerman University of Medical Sciences, Kerman, Iran

3- Assistant Professor of Dermatology, Department of Dermatology, Afzalipour School of Medicine, Kerman University of Medical Sciences, Kerman, Iran

4- Resident of Dermatology, Department of Dermatology, Afzalipour School of Medicine, Kerman University of Medical Sciences, Kerman, Iran

5- Assistant Professor of Dermatology, Department of Dermatology, Afzalipour School of Medicine, Kerman University of Medical Sciences, Kerman, Iran (Corresponding author; maaflatoonian@gmail.com)

Received: 12 June, 2017

Accepted: 2 February, 2018

ARTICLE INFO

Article type:

Original article

Keywords:

Niosomal zinc sulfate

Wart treatment

Clinical trial

Abstract

Background: There are different treatment modalities for common warts and all of them have side effects. Niosomal drug delivery systems have increased efficacy by enhanced transport of therapeutic agents through stratum corneum with decreased side effects. In this study, we assessed the efficacy of combined 2% niosomal zinc sulfate cream plus cryotherapy compared with combination of placebo plus cryotherapy.

Methods: Sixty patients with verruca vulgaris enrolled in this randomized clinical trial study. Patients were divided in 2 groups. Group A received 2% niosomal zinc sulfate cream and group B received placebo twice a day. Also, patients in both groups were treated with cryotherapy (liquid nitrogen) every other week. Treatment protocols continued for a maximum of 3 months or until total clearance of the lesions.

Results: Mean number of the sessions for complete remission was 4.5 ± 1.38 in group A and 5.36 ± 0.88 in group B and the difference between the two groups was statistically significant. Complete remission was observed in 60% in group A compared with 43.3% in group B that was not statistically significant.

Conclusion: Combination therapy with niosomal zinc plus cryotherapy can lead to faster and greater percentage clearance of the lesions without significant increase in adverse effects in comparison with cryotherapy plus placebo.

Copyright: 2018 The Author(s); Published by Kerman University of Medical Sciences. This is an open-access article distributed under the terms of the Creative Commons Attribution License (<http://creativecommons.org/licenses/by/4.0>), which permits unrestricted use, distribution, and reproduction in any medium, provided the original work is properly cited.

Citation: Farajzadeh S, Pardakhti A, Mohammadi S, Fadaei F, Khalili M, Mohebbi A, Aflatoonian M. A Randomized Clinical Trial of Using Niosomal Zinc Sulfate Plus Cryotherapy in Comparison with Placebo Along with Cryotherapy in Treatment of Common Wart. Journal of Kerman University of Medical Sciences, 2018; 25 (1): 1-8.

Introduction

Common wart is a common skin disease caused by various types of human papilloma virus (HPV) that can develop at any age being most prevalent in children and adult (1,2). In one study in Kerman the prevalence of common wart in school boy children was estimated to be about 15.26% (3). Lesions may clear without any treatment probably taking months to years (4). Development of the lesions especially in exposed sites and in large numbers can affect physical appearance and decrease the quality of patients' lives. Rarely, long-lasting untreated lesions can progress to premalignant and malignant lesions (5).

Today, there is no specific treatment for HPV. Choice of treatment modality depends on site and size of involvement, age and immune status of the patients. Treatments are classified to cytotoxic and immunomodulatory drugs, as well as ablative methods (2).

Cryotherapy is the first line treatment for common warts that leads to necrosis and cell death plus stimulation of immune system against HPV. Efficacy of cryotherapy in clinical trials is varied between 9 to 87 % (mean 49%) based on treatment intervals and each cycle duration of the freeze. Disadvantages of this method include frequent sessions of expensive therapy that takes a lot of time and days off with pain, probable blister and scar formation. Also, application of cryotherapy near nerves, tendons and nails and in persons with poor blood circulation needs caution (6).

Zinc sulfate as intralesional or topical formulation is another treatment for common warts. Although it has a good efficacy, side effects including severe pain of injection, erythema, swelling and risk of necrosis may limit its use (7).

Niosomes are new vesicular systems ranging in size from nanometer to micron composing nonionic surfactants and cholesterol. Since these niosomal systems have better drug

penetration through biological membranes with reduced adverse effects, so for the first time we decided to evaluate the efficacy of combination of 2% niosomal zinc sulfate cream plus cryotherapy in comparison with placebo plus cryotherapy (8,9).

Materials and methods:

We obtained Sorbitan monostearate (SpanTM 60), zinc sulfate heptahydrate ($ZnSO_4 \cdot 7H_2O$) and cholesterol from Merck, Germany. All other chemicals and solvents were in analytical grade and obtained from Merck, Germany, too.

Niosome preparation

Non-ionic surfactant vesicles (niosomes) were prepared by lipid film hydration method, fully described previously (10). Ephemeraly, 300 μ mole Span 60 and cholesterol (70/30 molar percent) was dissolved in 5 ml chloroform and the organic solvent was evaporated in a rotary evaporator (Heidolf, Germany) under reduced pressure at 65°C. The dried lipid film was put in a vacuum oven overnight for ensuring the trace organic solvent elimination. Zinc sulfate heptahydrate was dissolved in enough warm deionized water to form 2% w/v solution of Zn^{2+} and then used for hydration of dried lipid form at 65°C for 30 min. Niosomal suspension was maintained at room temperature for 24 h to complete the process of lipid vesicular bilayers hydration (11). Final full-hydrated niosomes were kept at refrigerator for further pharmaceutical studies; for clinical trial, the niosomal suspensions were used during 6 months after preparation.

Evaluation of physical properties of niosomes

The vesicular aggregation, apparent view/type of niosomes, and probable separation of Span 60 or cholesterol from lipid bilayers were evaluated by optical microscopy

(Hfxdx, Nikon, Japan) equipped by a picture transferring loop and related software (Dino Capture 20, Taiwan) to get some photomicrographs.

Size analysis of non-ionic surfactant vesicles (NSVs) was carried out by using static laser light diffraction method (Malvern Instruments, Master Sizer 2000E, UK).

Samples were stored in glass vials for 3 months and were withdrawn at regular time intervals (1 week and 3, 6 months)

and niosomal size measurement was done as a physical stability indicator.

Multilamellar vesicles (MLVs) were formed as depicted in Fig. 1. Mean volume diameter of Span 60 niosomes was $6.84 \pm 0.21 \mu\text{m}$, 48 h after preparation. Size distribution curves of prepared MLVs (Fig. 2) showed high physical stability of niosomes.

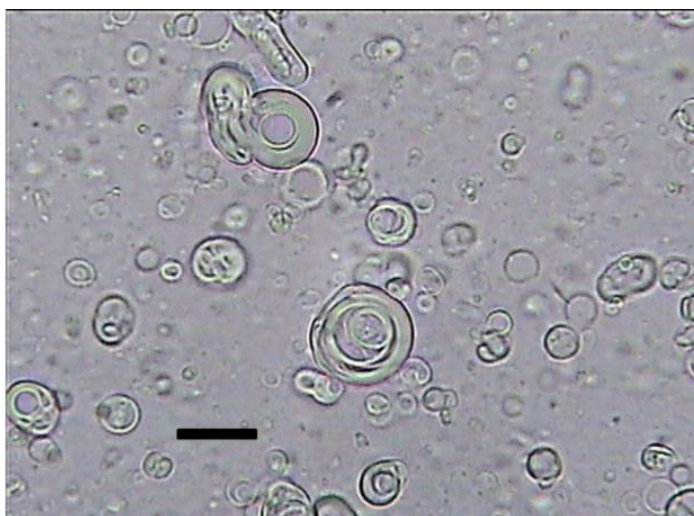

Fig1. Micrograph (40×10 magnifications) of zinc sulfate niosomal formulation composed of Span 60/cholesterol (70/30 molar percent); Scale bar = 5 μm .

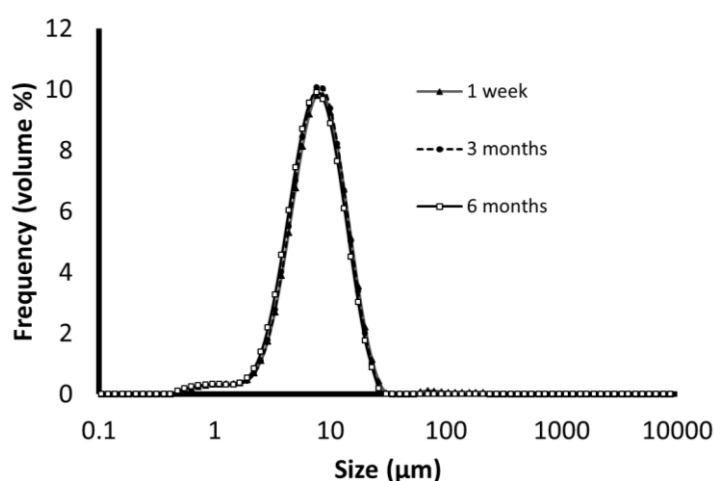


Fig 2. Size distribution and physical stability of zinc sulfate niosomal formulation composed of Span 60/cholesterol (70/30 molar percent) during 6 months storage at 4-8°C.

Clinical study design and performance

This is a double-blind randomized clinical trial that enrolled 60 patients with diagnosis of verruca vulgaris (common wart) in Afzalipour hospital and dermatologic clinics in Kerman. Exclusion criteria included lesions located on face, genitalia and periungual areas, patients' ages less than 12 months, immune suppression, pregnant or lactating women and those who had received any kind of treatments in advance.

After signing the informed consent form, patients were divided (simple randomization) in 2 groups by Mini Tab 16 (Mini Tab Inc.). Firstly, demographic features such as age, sex and site of the lesions were recorded. In each patient, one lesion with largest diameter (at least 6 millimeter) was evaluated. Then, we treated patients in groups A and B with 2% niosomal zinc sulfate and placebo cream twice a day, respectively. Both groups underwent two-double freeze-thaw cycle cryotherapy with liquid nitrogen every other week by cotton swab until a 2 millimeter white halo in the periphery of the lesion appeared. Duration of each cycle of cryotherapy depends on site and size of the lesion that varied between 5 to 30 seconds. Treatment was performed for a maximum of 3 months or until total clearance of the lesions, whichever occurred first. Patients were evaluated every two weeks, at baseline, 2, 4, 6, 8, 10, 12 weeks of treatment for treatment efficacy and possible adverse effects (pain, pruritus, hypo and hyper pigmentation, blister or scar formation). The efficacy was evaluated based on a reduction in lesion size. We measured size of the lesions by a standard scaled ruler in

largest diameter. Patients were followed up at 6 weeks after the end of the treatment for evaluation of probable recurrence.

Statistical analysis

We used mean \pm standard deviation and frequency for descriptive analysis, and chi-square test for evaluation of efficacy and side effects. In order to compare the 2 groups, we used "t test". We used SPSS version 20 for statistical analysis. P. value less than 0.05 was considered significant.

Results

Thirty patients in each group including 51.66% males and 48.33% females were enrolled into the study. Most of the lesions were located in upper limb (55%). Table 1 shows demographic features of the patients and site of involvement.

Difference between response rates in 2 groups was not significant after 7 sessions of treatment except in the sixth session (10 weeks after the start of treatment). Table 2 shows mean size of the lesions in both treatment groups.

Mean number of the required sessions for complete remission was 4.5 ± 1.38 in group A and 5.36 ± 0.88 in group B with a significant difference ($p=0.005$). Complete remission was observed in 60% of group A compared with 43.3% in group B ($p=0.30$). Percentage of complete remission between the two treatment groups was significantly different (Table 3).

Adverse effects such as pain, pruritus and hyper pigmentation were most prevalent in group A, but blister formation and hypopigmentation in group B (Table 4).

Table 1. Demographic features of the patients and location of involvement

Variables	Case group	Control group	Total	P. value	
Sex	Male	19(63.3%)	12(40%)	31(51.7%)	0.07
	Female	11(36.7%)	18(60%)	29(48.3%)	
Mean age(years)	28.8±8.84	26.70±9.77		0.71	
Site of the involvement	Upper limb	17(56.7%)	16(53.3%)	33(55%)	0.58
	Lower limb	12(40%)	11(36.7%)	23(38.3%)	
	Other locations	1(3.3%)	3(10%)	4(6.7%)	

Table 2. Size of the lesions (mean ±SD) during the sessions of the treatment in both groups

Treatment sessions	Size of the lesion (mm)		
	Case group	Control group	p. value
Basic	8.75±3.50	9.15±3.70	0.66
2Weeks	8.36±3.55	8.73±3.72	0.69
4Weeks	6.40±2.94	7.36±3.36	0.24
6Weeks	4.80±2.78	5.90±3.03	0.14
8Weeks	3.03±2.84	4.30±2.81	0.08
10Weeks	1.80±0.40	3.06±0.43	0.03
12weeks	1.13±0.30	1.73±0.39	0.23

Table 3. Complete remission in two treatment groups during the treatment

Treatment sessions	Case group N (%)	Control group N (%)	P value
6 weeks	1(3.3)	0(0)	0.31
8 weeks	10(33.3)	2(6.7)	0.01
10 weeks	16(53.3)	4(12.3)	0.001
12 weeks	18(60)	13(43.3)	0.19

Table 4. prevalence of adverse effects in both treatment groups

Adverse effects	Case group N (%)	Control group N (%)	Total N (%)	P. value
Pain	26(52)	24(48)	50	0.49
Blister	15(46.9)	17(53.1)	32	0.60
Pruritus	10(71.4)	4(28.6)	14	0.006
Hyperpigmentation	8(57.1)	8(42.9)	16	0.54
hypopigmentation	12(46.2)	14(53.8)	26	0.60

Discussion

Zinc is an immune system regulator and its deficiency may lead to lymphocyte T dysfunction. Zinc can induce stimulation of cytotoxic T lymphocytes that may lead to clearance of warts by increased production of interferon α . Oral zinc sulfate supplements have a significant role in the treatment of refractory lesions in patients with low serum level of zinc. But its prescription in patients with normal serum level of zinc has no benefit in comparison with placebo. Also, oral zinc sulfate can lead to gastrointestinal adverse effects

such as vomiting, nausea and abdominal pain. Topical formulation of zinc can lead to clearance of infected keratinocytes with HPV by stimulation of immune system through induction of inflammation and necrosis. Topical zinc sulfate may cause pain, tenderness, swelling and erythema at the location of application and may lead to scar formation (12-15).

Niosomal drug delivery system has more stability and skin absorption that can lead to slow release of drugs, lower side effects and higher efficacy. In this study the rate of complete

response with combination of niosomal zinc sulfate plus cryotherapy was 60% in comparison with combined cryotherapy and placebo that was 43.3%, but the difference was not statistically significant. Also, clearance percentage after 8 weeks of treatment was significantly higher in niosomal group than control group (8,9).

In one study by Sharquie and colleagues in 2002, injection of 2% zinc sulfate was evaluated with complete response rate of 98.2%. 80.92% of the patients had complete clearance after only one treatment session. Although this result was better than our findings, but adverse effects including tenderness, swelling, erythema and hyper pigmentation was observed in 100% of the patients in Sharquie's study. Also, because of possible risk of necrosis in acral regions, intralesional form of the drug cannot be used (16).

In another study by Sharquie and colleagues in 2007, 10% and 5% zinc sulfate were implicated for plane warts for 4 weeks with response rates of 85.7% and 42.8%, respectively. However, response rate for verruca vulgaris was very low (11%, 5%, respectively). In our study the response rate for common wart was superior to the study conducted by Shaquie and colleagues (17). This can be due to combined treatment with cryotherapy, longer duration of treatment and also better absorption of niosomal forms of zinc.

In another study by Khatter in 2007, complete clearance with 20% zinc oxide ointment was 50%. Despite higher percentage of zinc in Khatter's study compared to our research (20% in their study vs. 2% in our study), complete response was lower in their study. In our study combination therapy was used with cryotherapy, while in Khatter's study mechanical keratolytic method (stone) was applied as combination (18).

In our research, mean count of sessions for case and control groups were 4.5 ± 1.38 and 5.36 ± 0.88 , respectively that was statistically significant. In contrast, in khattar's study differences between mean numbers of the sessions were not significant and it was longer than our study. Also, in our study all of the treated lesions were vulgaris type, but, in khattar's study 32% of the lesions were plane wart and because of lower thickness, better response to treatment was dominant (18).

In our study, addition of niosomal zinc sulfate to cryotherapy did not lead to a significant increase in adverse effects. In Khattar's study (18), swelling was reported predominantly in zinc sulfate group. In our study in comparison with Khattar's study, we observed more side effects including pruritus, pain and hyperpigmentation. Of course this finding is predictable in combined treatment of niosomal zinc sulfate with cryotherapy.

So, niosomal zinc sulfate combined with cryotherapy led to faster improvement in comparison with other treatment modalities such as cryotherapy, keratolytic compound of salicylic acid as well as lactic acid and combined conventional zinc sulfate with mechanical keratolytic methods (18).

Conclusion

According to our findings, addition of niosomal zinc sulfate to cryotherapy can lead to rapid remission of the lesions and higher percentage of clearance without a significant increase in adverse effects. We recommend another study to evaluate the efficacy of treatment with niosomal zinc sulfate as monotherapy with conventional formulation.

References

1. Sterling JC, Gibbs S, Haque Hussain SS, Mohd Mustapa MF, Handfield-Jones SE. British Association of Dermatologists' guidelines for the management of cutaneous warts 2014. *Br J Dermatol* 2014; 171(4):696-712.
2. Gerlero P, Hernández-Martín Á. Treatment of warts in children: An update. *Actas Dermo-Sifiliográficas (English Edition)*. 2016; 107(7):551-8.
3. Zandi S, Rezayian H. Prevalence of warts in boy's high school students in the city of Kerman [dissertation]. Kerman University of Medical Sciences; 1997. Persian
4. Bruggink SC, Eekhof JA, Egberts PF, van Blijswijk SC, Assendelft WJ, Gussekloo J. Natural course of cutaneous warts among primary schoolchildren: a prospective cohort study. *Ann Fam Med* 2013; 11(5):437-41.
5. Committee on Guidelines of Care, Drake LA, Ceilley RI, Cornelison RL, Dobes WL, Dorner W, Goltz RW, et al. Guidelines of care for warts: human papillomavirus. *J Am Acad Dermatol* 1995; 32(1):98-103.
6. Ahmed I, Agarwal S, Ilchyshyn A, Charles-Holmes S, Berth-Jones J. Liquid nitrogen cryotherapy of common warts: cryo-spray vs. cotton wool bud. *Br J Dermatol* 2001; 144(5):1006-9.
7. Bagherani N, Smoller BR. An overview of zinc and its importance in dermatology-Part II: The association of zinc with some dermatologic disorders. *Glob Dermatol* 2016; 3(5): 337-50.
8. Mohammadi S, Khazaeli P, Shamsi Meymandi S, Aflatoonian M, Khalili Meybodi M, Mehrolhasani N, et al. Comparison of the efficacy of isotretinoin 0.05% niosomal gel versus adapalene 0.1% gel in the treatment of acne vulgaris: A randomized, double-blind clinical trial. *Dermatology and Cosmetic* 2016; 7(2):66-73. In Persian
9. Aflatoonian M, Fekri A, Rahnam Z, Khalili M, Pardakhti A, Khazaeli P, et al. The efficacy of combined topical niosomal dapsone gel and intralesional injection of meglumine antimoniate in comparison with intralesional meglumine antimoniate and cryotherapy in the treatment of cutaneous leishmaniasis. *Journal of Pakistan Association of Dermatology* 2017; 26(4):353-60.
10. Pardakhty A, Shakibaie M, Daneshvar H, Khamesipour A, Mohammadi-Khorsand T, Forootanfar H. Preparation and evaluation of niosomes containing autoclaved *Leishmania major*: a preliminary study. *Journal of Microencapsulation* 2012; 29(3):219-24.
11. Pardakhty A, Moazeni E, Varshosaz J, Hajhashemi V, Najafabadi AR. Pharmacokinetic study of niosome-loaded insulin in diabetic rats. *Daru* 2011; 19(6): 404-11.
12. Al-Gurairi FT, Al-Waiz M, Sharquie KE. Oral zinc sulphate in the treatment of recalcitrant viral warts: randomized placebo-controlled clinical trial. *Br J Dermatol* 2002; 146(3):423-31.
13. Moniem EA, Genedy RM, Moussa R. Oral zinc sulfate in the treatment of recalcitrant warts. *Egyptian Journal of Dermatology and Venerology* 2016; 36(2):34-8.
14. Yaghoobi R, Sadighha A, Baktash D. Evaluation of oral zinc sulfate effect on recalcitrant multiple viral warts: a randomized placebo-controlled clinical trial. *J Am Acad Dermatol* 2009; 60(4):706-8.
15. Hassan I, Bhat T, Altaf H, Sameem F, Masood Q. Role of oral zinc sulphate in warts-a placebo

- controlled, single-blinded study. *Our Dermatol Online* 2013; 4(1):24-7.
16. Sharquie KA, Al-Nuaimy AA. Treatment of viral warts by intralesional injection of zinc sulphate. *Ann Saudi Med* 2002; 22(1-2):26-8.
 17. Sharquie KE, Khorsheed AA, Al-Nuaimy AA. Topical zinc sulphate solution for treatment of viral warts. *Saudi Med J* 2007; 28(9):1418-21.
 18. Khattar JA, Musharrafieh UM, Tamim H, Hamadeh GN. Topical zinc oxide vs. salicylic acid-lactic acid combination in the treatment of warts. *Int J Dermatol* 2007; 46(4):427-30.