

Schwannoma of Gingiva: a rare case report

Khadijeh Abdal, M.Sc.¹, Parya Emamverdizadeh, M.Sc.²

1- Assistant Professor, Department of Oral and Maxillofacial Pathology, Faculty of Dentistry, Ilam University of Medical Sciences, Ilam, Iran
(Corresponding author; E-mail: dr.faribaabdal@yahoo.com)

2- Associate Professor, Department of Oral and Maxillofacial Pathology, Faculty of Dentistry, Tabriz University of Medical Sciences, Tabriz, Iran

Received: 6 October, 2018

Accepted: 24 December, 2019

ARTICLE INFO

Article type:

Case Report

Keywords:

Schwannoma

Peripheral nerve sheath

Neoplasm

Gingival

Abstract

Schwannoma is a rare benign neural neoplasm derived from Schwann cells of the peripheral nerve sheath. Schwannoma accounts for 25% to 48% of all neoplasm cases in the head and neck region. Oral Schwannoma is an uncommon soft tissue tumor comprising of 1% of all Schwannomas. Tongue is the most common location for oral schwannoma. Occurrence of gingival schwannoma is very rare and less than 10 cases have been reported until now. Oral Schwannoma occurs in the mean age of 43 years. In this report, we present a unique case of Schwannoma in a 12-year-old male child with an enlarged semi-firm nodule on the labial surface of his right mandibular gingiva canine tooth which was provisionally diagnosed as pyogenic granuloma. However, the histopathologic and immunohistochemical evaluation confirmed it as Schwannoma. After the surgery, the patient was kept under regular follow-up and there has been no evidence of recurrence during the last 15 months.

Copyright: 2019The Author(s); Published by Kerman University of Medical Sciences. This is an open-access article distributed under the terms of the Creative Commons Attribution License (<http://creativecommons.org/licenses/by/4.0>), which permits unrestricted use, distribution, and reproduction in any medium, provided the original work is properly cited.

Citation: Abdal KH, Emamverdizadeh P. Schwannoma of Gingiva: a rare case report. *Journal of Kerman University of Medical Sciences*, 2019; 26(6): 494-498.

Introduction

Schwannoma, known as neurilemmoma, neurinoma, perineural fibroblastoma or Schwann cell tumor, was first described by Verocay in 1910 (1). Schwannoma is a slow growing painless encapsulated tumor that typically arises from perineural nerve sheath. It occurs more often in females with mean age of 43 years (2). Often, Schwannoma is benign, although some malignant cases have been reported especially with Von Recklinghausen's disease (3). Schwannoma accounts for 25% to 48% of all neoplasm cases occur in the head and neck region. Oral schwannomas (OS) is an uncommon soft

tissue tumor comprising of 1% of all Schwannomas (4). Tongue is the most common location for oral Schwannoma. Although the tumor can occur almost anywhere in the mouth, gingival involvement is very rare. This tumor may arise both in soft tissue and bone (3, 5). Histologically, Schwannoma, usually, demonstrates two microscopic patterns of Antoni type A and Antoni type B. In Antoni A, tissue is characterized by streaming fascicles of spindle-shaped Schwann cells that often form a palisaded arrangement around the central acellular, eosinophilic areas known as Verocay bodies (6, 7). In Antoni B, tissue is less cellular and organized; the spindle cells are

randomly arranged within a loose myxomatous stroma (3). Many variant types of schwannoma have been explained, such as plexiform, cellular, epithelioid, and ancient Schwannomas (2, 6).

Immunohistochemically, Schwannoma tumor cells show positive for S-100, Leu-7, Myelin basic protein, vimentine and neuron-specific enolase showing their neural origin and differentiating them from other soft tissue tumors (3, 4).

Clinically, Schwannoma of oral soft tissue may resemble other lesions such as peripheral giant cell granuloma, and pyogenic granuloma, neurofibroma, fibroma, lipoma, peripheral ossifying fibroma and mucocele (1,3,5).

Since there has been fewer than 10 cases of gingival Schwannoma in the literature, we report a patient with schwannoma in gingiva as a rare case.

Case report

A 12-year-old male child referred to Oral Medicine Department of Ilam Dental School with chief complaint of an asymptomatic swelling on his labial surface of the right mandibular gingiva canine tooth that had been occurred since 5 months ago. The past medical and dental history of the patient was not relevant to the present swelling. Intraoral examination revealed a painless soft and semi-firm enlargement with smooth surface on the labial of right mandibular gingiva canine tooth, measuring about 1.5cm × 2 cm in diameter covered by normal mucosa (Figure 1). An intraoral periapical radiograph was taken that revealed no relation of swelling with the bone (Figure 2). Clinically, provisional diagnosis of

pyogenic granuloma was raised. Then, the patient underwent surgery with local anesthesia and surgical excision of the mass was performed and the specimen was fixed in a 10% formalin solution and sent for histopathological evaluation. Histopathological examination of the specimen showed a well-circumscribed mass with proliferation of spindle-shaped cells that formed a palisade pattern in some areas (Antoni A type), surrounding eosinophilic structures with rows of nucleus, some of collagen and basal laminar material looks like verocay bodies. Other regions were composed of mixoid stroma with fewer cells and an irregular arrangement of spindle cells without palisading (Antoni B type) (Figure 3). The spindle-shaped cells were strongly positive for S-100 protein (Figure 4). Based on the histopathological and immune-histochemical findings, the diagnosis of Schwannoma was confirmed.

Currently, the patient is under regular follow-up and there has been no evidence of recurrence during the last 15 months (Figure 5).

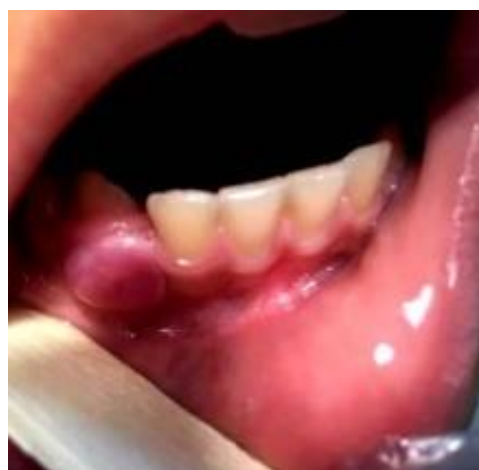

Figure 1. Clinical examination of tumor mass revealed a lesion located in the right gingival mucosa at the canin teeth.



Figure 2. Periapical radiograph of the patient showing intact alveolar bone

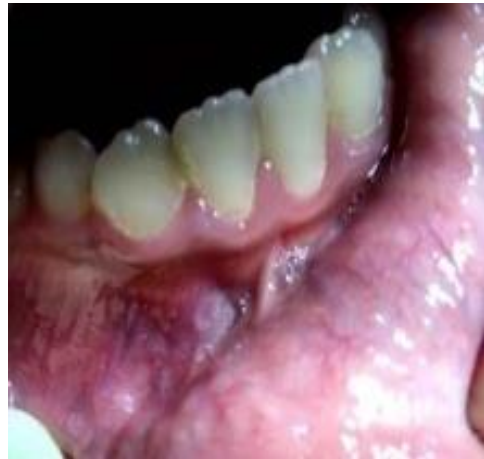

Figure 5. No sign of recurrence after 15 month (×40)

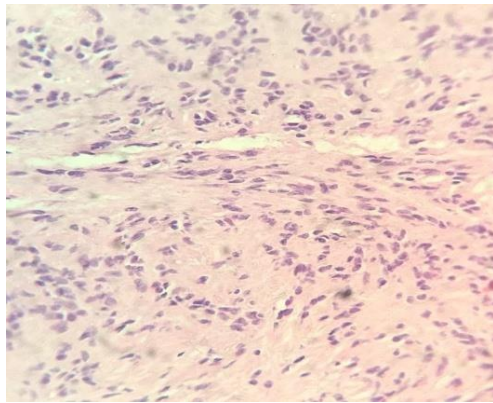


Figure 3. Histopathological slide of the tissue showing: (a) Spindle-shaped cells arranged in Antoni A configuration surrounding eosinophilic structures suggestive of Verocay bodies (H and E staining ×10)

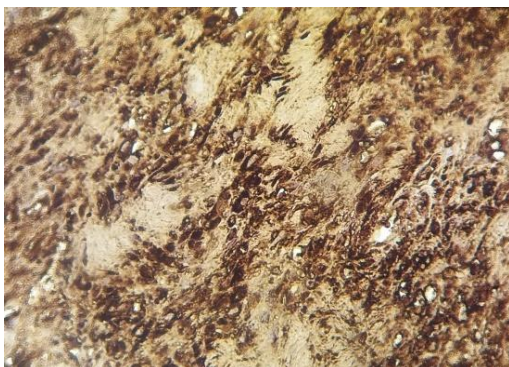


Figure 4. Immunohistochemical staining Tumor cells revealed a diffuse positive expression for S - 100 (×40).

Discussion

Intraoral schwannoma is a rare solitary, benign, slow-growing and encapsulated nodular neoplasm with unknown etiology, but it is apparently originated from neural sheath of branches of the mental nerve and inferior alveolar nerve (7). The first case of OS (ancient type) was reported by Eversole and Howell in 1971 (8). OS is usually asymptomatic but in intraosseous regions, it can be seen with pain and paresthesia. About 25-45% of all schwannomas occur in the head and neck, but only 1% has an intraoral origin (9). Tongue, palate, mouth floor, buccal mucosa, lip and jaw are the most common locations for OS. In extremely rare cases, OS occurs in the gingival region (10). A review from 1960 to 2006 showed only five cases on gingival mucosa (8). Another review study from 2001 to 2011, showed only one case arisen from the gingival mucosa and other cases had been in another intraoral locations such as tongue, mouth floor and intrabony mandible (9). Based on our knowledge, fewer than 10 cases of gingiva OS have been reported so far. Therefore, gingiva schwannoma seems to be

extremely rare. In this paper, we presented a unique case of schwannoma in the mandibular gingiva. Mostly, OS manifestation is during the fourth decade of life and there is a slight female predilection (3). Mostly, OS has been reported in the fourth decade of life, whereas our case was a 12 years old child.

Grossly, schwannoma is a gelatinous or cystic mass with or without capsule (6). Histo-pathologically, OS is categorized to two types of tissue arrangements; Antoni A and B. Degenerative changes such as hemorrhage, hemosiderin deposits inflammation, fibrosis and nuclear atypia can be seen in some older tumors known as ancient neurilemmomas (1, 5). However, these changes are benign and pathologists must be careful not to mistake these alterations with evidence of a sarcoma. In this case, the tumor was encapsulated and composed of both Antoni A and B appearance with verocay bodies.

Radiographically, computed tomography (CT) and magnetic resonance imaging (MRI), could be used for the diagnosis of all OS cases, especially to demonstrate schwannoma in mouth floor (2,7). In our patient cause of

localized and non-intraosseous lesion, was performed only periapical radiography evaluation.

The prognosis of schwannoma is good and surgical excision is the treatment of choice (9). Recurrence and malignant transformation does not occur or is extremely rare (10). In the present case, also, the 15-month follow-up period shows no evidence of recurrence.

On the base of available reports in the medical literature, the presented case is the tenth case of OS deriving from gingiva,

Conclusion

Oral schwannoma in gingiva is an extremely rare tumor and this could be the presentation of OS gingival in a pediatric age group patient. It is necessary for clinicians to consider schwannoma in the differential diagnosis of any painless gingival nodule and to rule out other etiologic factors of gingival enlargement. The aim of this case report was to report this uncommon type of schwannoma in a 12-year-old child.

Conflicts of interest

There is no conflict of interest.

References

1. Nishijima Sakanashi E, Sonobe J, Chin M, Bessho K. Schwannoma located in the upper gingival mucosa: case report and literature review. *J Maxillofac Oral Surg* 2015; 14(Suppl 1):222-5.
2. Bajpai M, Pardhe N. Ancient schwannoma of gingiva - A rare case report. *J Indian Soc Periodontol* 2017; 21(3):234-6.
3. Purwar P, Dixit J, Singhal D, et al. Schwannoma of gingival: a rare case report. *J Orofac Res* 2014; 4(3):189-92.
4. Bajpai M, Pardhe N. Ancient schwannoma of gingival-A rare case report. *J Indian Soc Periodontol* 2017; 21(3):234-6.
5. Amirchaghmaghi M, Salehinejad J, Basirat M, Delavarian Z, Javadzade A, Forouzanfar A. Gingival ancient schwannoma review of literature and a case report. *Journal of Applied Sciences* 2010; 10(23):3137-40.
6. Muruganandhan J, Prasad TS, Selvakumar T, Kumar SN. Ancient neurilemmoma: a rare oral

- tumor. *J Oral Maxillofac Pathol* 2013; 17(3):447-50.
7. Gainza-Cirauqui ML, Eguía-Del Valle A, Martínez-Conde R, Coca-Meneses JC, Aguirre-Urizar JM. Ancient schwannoma of the hard palate. An uncommon case report and review. *J Clin Exp Dent* 2013; 5(1):e62-5.
 8. Ishii J, Kamiya T, Wadamori T, Iijima S, Nagasawa H, Satoh M, et al. Neurilemoma of the oral and maxillofacial region. *Japanese Journal of Oral and Maxillofacial Surgery* 2001; 47(2):89-92.
 9. Kun Z, Qi DY, Zhang KH. A comparison between the clinical behavior of neurilemmomas in the neck and oral and maxillofacial region. *J Oral Maxillofac Surg* 1993; 51(7):769-71.
 10. Handschel J, Heikaus S, Depprich R, Kübler NR, Yekta SS, Smeets R, et al. Intraoral schwannoma: review of the literature and presentation of a rare case. *Cranio* 2012; 30(2):150-3.