



Does Repeating Transurethral Resection of Bladder Tumors Change Treatment Plan for All T1 Tumors?

Reza Mohammadi¹, Hamid Pakmanesh¹, Morteza Hashemian², Abbas Poorjafari¹

¹Department of Urology, Kerman University of Medical Sciences, Kerman, Iran

²Department of Anesthesiology and Pain Medicine, Kerman University of Medical Sciences, Kerman, Iran

Abstract

Background: The main problem in the proper management of non-muscle invasive bladder cancer (NMIBC) is the under-staging of lesions after initial transurethral resection of bladder tumor (TURBT). Under staging is much more evident in T1 tumors when the detrusor muscle is absent. So, we evaluated under-staging and residual tumors in patients with complete initial TURBT whose initial pathological samples revealed the presence of the detrusor muscle.

Methods: In this prospective study performed in Bahonar hospital, Kerman, Iran, from August 2018 to April 2020, 51 patients with newly diagnosed T1 bladder tumors were enrolled according to our criteria and underwent standard Re-TURBT about eight weeks after the initial TURBT.

Results: Of 51 patients who underwent Re-TURBT, 12 (23.5%) had tumors, of whom eight had microscopic, and four had macroscopic tumors. None of them were upstaged or upgraded. There was a statistically significant relationship between the presence of tumors in Re-TURBT and the size of the primary tumor (>3 cm) and the number of tumors (>1). No changes were observed in the stage and grade of the disease, besides, the treatment plan of patients did not change despite imposing financial burdens on patients and the healthcare system.

Conclusion: Re-TURBT is not necessary for all superficial bladder tumors, especially in the case of complete initial TURBT, and also in the presence of the detrusor muscle in the pathological sample and when the tumor is single and less than three centimeters in size.

Keywords: Bladder cancer, Transurethral resection of tumor, T1 tumor

Citation: Mohammadi R, Pakmanesh H, Hashemian M, Poorjafari A. Does repeating transurethral resection of bladder tumors change treatment plan for all T1 tumors? *Journal of Kerman University of Medical Sciences*. 2023;30(4):213-217. doi:10.34172/jkmu.2023.35

Received: February 2, 2023, **Accepted:** May 15, 2023, **ePublished:** August 20, 2023

Introduction

Bladder cancer is the most expensive cancer to treat over a patient's lifetime (1). Bladder cancers include urothelial carcinoma (90%), squamous cell carcinoma (5%), and adenocarcinoma (less than 2%) (2). Urothelial carcinomas are divided into two general categories: muscle-invasive bladder cancer (MIBC) and non-muscle invasive bladder cancer (NMIBC). The recent group comprises low- or high-grade and non-invasive papillary neoplasms (Ta), carcinoma in situ (CIS), and urothelial carcinoma with invasion into the lamina propria (T1), which makes up approximately 70% of all bladder urothelial carcinomas (3).

Initial transurethral resection of bladder tumor (TURBT) is the first step for the proper treatment of these tumors. During this procedure, it is critical to obtain a good specimen for histopathological examination and clinical staging to acquire additional information about the tumor, which can influence the initial treatment and prognosis, including the size, location, multiplicity, and

grade of the tumor, as well as the presence of associated CIS (4). Minor bleeding and irritative symptoms are common side effects immediately during the postoperative period. The major complications of uncontrolled hematuria and clinical bladder perforation occur in 1%-6.7% of cases (5). The main problem for the proper management of these tumors is the under-staging of lesions and residual tumors after initial TURBT (6). Under-staging is much more likely in T1 tumors when the detrusor muscle is absent compared to when the muscle is present in the specimen (64% vs. 30%) (7).

According to American Urological Association (AUA) guidelines, it is recommended to repeat TURBT (Re-TURBT) at the primary tumor site within six weeks of the initial TURBT to include muscularis propria in patients with incomplete initial resection and those with stage T1 disease (8). These guidelines also recommend the consideration of repeating TURBT in patients with high-risk and high-grade Ta tumors. In this study, we



evaluated residual tumor and staging errors during the Re-TURBT of newly diagnosed patients with T1 bladder tumors who had complete initial TURBT and showed the presence of the detrusor muscle in initial TURBT.

Material and Methods

Participants

The patients newly diagnosed with bladder tumors from August 2018 to April 2020 were included. The study was carried out according to AUA guidelines for Re-TURBT (8), and it was approved by the Ethics Committee of the Kerman University of Medical Sciences (IR.KMU.AH.REC.1398.091); also, informed consent was obtained from the patients to participate in the study. The patients underwent standard TURBT. Epidemiologic characteristics of patients (age, gender), tumor size, the number and morphology of tumors, and other pathologic findings were recorded. The patients who had T1 bladder tumors with their pathologic samples revealing the presence of the detrusor muscle layer were selected. Those with incomplete tumor resection during initial TURBT were excluded from the study. Also, patients with a history of radiotherapy and chemotherapy were excluded. Altogether, 51 patients fulfilling our criteria were selected.

Clinical Procedures

The Re-TURBT surgery was performed about eight weeks after the initial TURBT in all cases. After the patient was placed in the lithotomy position and under general anesthesia, cystoscopy was performed using 30° and 70° lenses, carefully checking all the bladder walls. For describing the cystoscopic view of previously resected sites, we used three categories i.e., macroscopic, slough, or scar. Then, previous tumor sites and residual or suspicious lesions were resected by a double-sheath (26 Fr) resectoscope and continuous irrigation water. In all cases, the resection was associated with the monopolar current, and deep resection was performed. After the procedure, the 20-24 Fr (3-way) catheter was inserted with continuous bladder irrigation. The main outcomes recorded during Re-TURBT were under-staging and the presence of residual tumors. Major complications directly related to Re-TURBT were considered uncontrollable hematuria and clinical bladder perforation.

Statistical Analysis

The duration of surgery and admission were recorded for data analysis that was performed using SPSS statistical software (version 22.0). Frequency was used to describe qualitative variables, and the mean, median, and standard deviation were utilized to present quantitative variables.

Results

From August 2018 to April 2020, 51 patients admitted

to Bahonar hospital of Kerman, Iran, were enrolled according to our criteria and underwent standard Re-TURBT about eight weeks after the initial TURBT.

Patients’ features, initial tumors’ characteristics, and Re-TURBT findings have been shown in Table 1.

Of 51 patients, 12 (23.5%) revealed residual tumors in Re-TURBT; however, there was no upstaging or upgrading. Four patients had macroscopic tumors (two at the previous site and two at a different site). Eight patients had microscopic tumors (six sloughs and two scars). More than half of patients (66.7%) with residual tumors in Re-TURBT had multiple (>1) initial tumors (Figure 1), and nearly all of them (91.7%) had large (>3 m) tumors at admission (Figure 2). Tumor size ($P<0.0001$) and multiple tumors ($P=0.003$) were significantly associated with the presence of tumor in Re-TURBT. Comparisons of various prognostic markers between patients without tumors (group 1) and those with tumors (group 2) in Re-TURBT have been shown in Table 2. No major complications were recorded for Re-TURBT.

Table 1. Patients’ demographic and clinical variables

Variables	No. (%) / mean (SD)
Gender	
Male	44 (86.3)
Female	7 (13.7)
Number of tumors	
Single	36 (70.6)
Multiple	15 (29.4)
Size of tumor	
< 1	7 (13.7)
1-3	23 (45.1)
> 3	21 (41.2)
Morphology	
Solid	14 (27.5)
Papillary	37 (72.5)
Grade	
Low	33 (64.7)
High	18 (35.3)
Re-TURBT cystoscopic view	
Scar	10 (19.6)
Slough	37 (72.5)
Macroscopic tumor	4 (7.8)
Re-TURBT pathology	
Without tumor	39 (76.5)
T1low	8 (15.7)
T1high	4 (7.8)
Age (y)	60.31 ± 9.23
Mean Re-TURBT duration (min)	50.29 ± 13.43
Mean hospital stay (day)	0.7
Mean time between TURBT & Re-TURBT (day)	39.17 ± 10.68

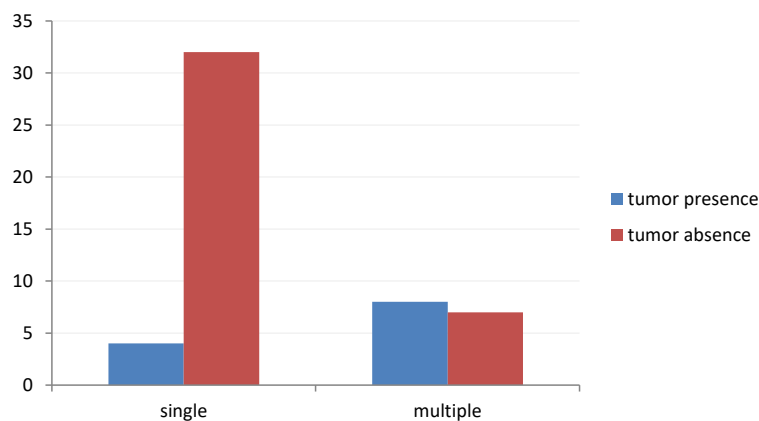


Figure 1. Comparison of the number of primary tumors between patients with and without tumors in RE-TURBT

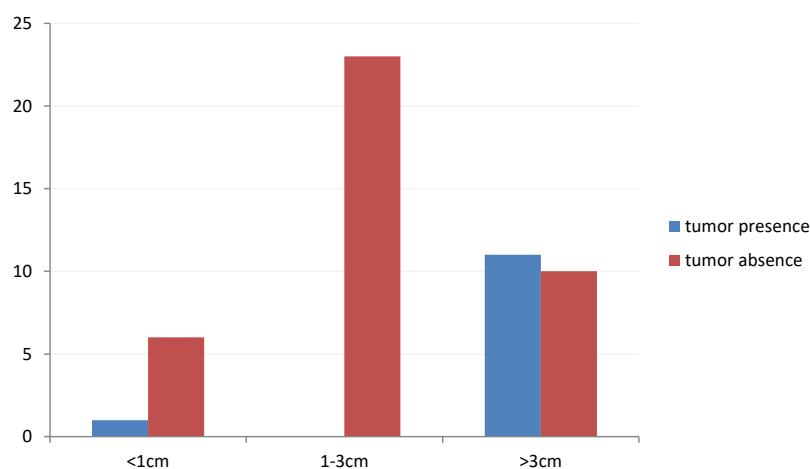


Figure2. Comparison of primary tumor size between patients with and without tumors in RE-TURBT

Discussion

In our study, all cases revealed the detrusor muscle during the initial TURBT, while in a study by Gaya et al (9), 22 (46%) out of 47 patients did not have the detrusor muscle in their initial pathological sample. In another study by Han et al (10), among 55 patients, only 17 (30.4%) revealed the detrusor muscle in the primary pathological specimen. Gill et al (11) studied 52 patients, 16 of whom (30.7%) did not have the detrusor muscle in the initial TURBT sample. El-Barky et al (12) initially started their study on 100 patients, but 14 patients were excluded due to the lack of the detrusor muscle in primary TURBT. Cumberbatch et al (13) performed a systematic review and found that the detrusor muscle was present in 30%-100% of primary TURBT cases.

In our study, 51 patients with T1 bladder tumors underwent Re-TURBT only 12 patients (23.5%) had residual tumors, four patients had macroscopic tumors, and eight patients had microscopic tumors, which was similar to the initial staging and grading. In Gaya and colleagues' study (9), out of 47 patients with high-grade superficial tumors (Ta & T1), ten patients (21%) had residual tumors in Re-TURBT, eight cases (17%) had

tumors similar to the initial ones, and two patients (4.2%) had upstaging; these two patients did not have detrusor muscle in their initial TURBT. In Han and colleagues' study (10), out of 55 patients with superficial tumors (Ta & T1), 36 patients (65.4%) had tumors in Re-TURBT, nine of whom (16.1%) revealed upstaging. In the study of Gill et al (11), out of 52 patients with superficial tumors (Ta & T1), 23 patients (44.2%) had tumors in Re-TURBT, and 12 patients (23.1%) had upstaging. Dwivedi et al, in their study (14) on 42 patients with superficial tumors (Ta&T1), reported that 12 patients (28.5%) had residual tumors in Re-TURBT and five patients (11.9%) had upstaging. In another study by Schwaibold et al (15) on 136 patients with T1 tumors, 71 patients (52%) revealed tumors in Re-TURT, and histopathological changes associated with poor prognosis (> T1 or association with Tis) were observed in 21% of the patients. In the study by El-Barky et al (12), out of 75 patients with superficial tumors (except for low-grade Ta) who revealed the detrusor muscle in the initial TURBT, 30 patients (40%) had tumors in Re-TURBT, 18 (24%) of whom had visible tumors, and 12 cases (16%) had microscopic tumors; in addition, 18 patients (24%) had upstaging, which caused

Table 2. Comparison of patients' demographic and clinical variables between those with and without tumor in Re-TURBT

Variables	Group 1	Group 2	P value
Age	60±9.11	61.33±9.93	0.66
Gender			
Male	32 (82.1)	12 (100)	0.17
Female	7 (17.9)	0 (0)	
Number			
Single	32 (82.1)	4 (33.3)	0.003
Multiple	7 (17.9)	8 (66.7)	
Size			
<1	6 (15.4)	1 (8.3)	0.0001 ≥
1-3	23 (59)	0	
>3	10 (25.6)	11 (91.7)	
Morphology			
Solid	10 (25.6)	4 (33.3)	0.71
Papillary	29 (74.4)	8 (66.7)	
Grade			
Low	25 (64.1)	8 (66.7)	1
High	14 (35.9)	4 (33.3)	
Re-TURBT Cystoscopic view			
Scar	8 (20.5)	2 (25)	1
Slough	31 (79.5)	6 (75)	
The time between TURBT & Re-TURBT (day)	38.30±10.54	42±11.12	0.16

a change in their treatment plan. Cumberbatch et al (13) during a systematic review on Re-TURBT in high-risk non-muscle invasive bladder tumors reported residual lesions in 17-67% of patients with Ta and 71-20% of patients with T1; moreover, upstaging occurred in 0-8% of cases with Ta tumors and 0-32% of those with T1 tumors. Miladi and colleagues (6), in their review, found that Re-TURBT corrected the initial staging errors in 49-9% of cases and detected tumors in 26-83% of cases. In addition, 2-28% of primary T1 tumors revealed muscle invasion in Re-TURBT. Naselli et al (16), in a systematic review meta-analysis, reported a pooled prevalence of ~50% for residual tumors and 10% for progression to an invasive disease during Re-TURBT for T1 tumors. In a report by Grimm et al (17) on 83 patients with superficial bladder tumors who underwent Re-TURBT, tumors were present in 33% of the cases, and five patients (6%) underwent radical cystectomy upon Re-TURBT findings. The comparison between studies was shown in Table 3.

The differences between the findings of the present study and those of other studies regarding the prevalence of upstaging may be because, in the present study, patients who had macroscopic tumors in the primary TURBT or those whose primary pathology specimens lacked the detrusor muscle were excluded. In our study, 91.7% of the patients who had a tumor in Re-TURBT had a primary tumor larger than 3 cm, and also, 66.7% of these patients

Table 3. The comparison of studies in terms of residual tumor

Study	Residual tumor (%)
Our study	23.5
Gaya et al (9)	21
Han et al (10)	65.4
Gill et al (11)	44.2
Grimm et al (17)	33
Cumberbatch et al (13)	17-67 (Ta) 71-20 (T1)
Dwivedi et al (14)	28.5
Schwaibold et al (15)	52
Miladi et al (6)	26-83
Naselli et al (16)	50

had multiple tumors. The presence of residual tumors in Re-TURBT was significantly associated with the size and number of primary tumors. In our study, initial pathological features (stage & grade) and initial tumor appearance (sessile or papillary) had no statistically significant relationship with the presence of the tumor in Re-TURBT. In a study by Dwivedi et al (14), similar to our study, tumor presence in Re-TURBT was significantly associated with the size (>3 cm) and number (>3) of tumors. But contrary to our study, tumor appearance (solid), grade (high), and history of multiple TURBTs were significantly associated with tumor presence in Re-TURBT. In Gill and colleagues' study (11), tumor stage, tumor grade, and tumor appearance (solid or papillary) were significantly associated with both tumor presence and upstaging in Re-TURBT. In addition, CIS had a significant correlation with the presence of residual tumor, while the absence of the detrusor muscle in the initial TURBT specimen was significantly associated with progression to muscle-invasive disease.

Conclusion

As mentioned in most studies and guidelines, the absence of the detrusor muscle has been suggested as a strong and important factor for Re-TURBT in superficial bladder tumors. In this study, we evaluated the findings of Re-TURBT in patients with newly diagnosed T1 bladder tumors who had complete initial TURBT and the detrusor muscle in their initial TURBT pathology specimens. Tumor size greater than 3 cm and multiple tumors were strong predictors for tumor presence in Re-TURBT. According to the findings of our study, only a small percentage of the patients had tumors in Re-TURBT, and none revealed a change in disease stage or grade and treatment plan. Therefore, we suggest that Re-TURBT is unnecessary for all superficial bladder tumors, especially in the case of complete initial TURBT, in the presence of the detrusor muscle in pathological samples, and in patients with single tumor or with tumors smaller than 3 cm.

Acknowledgments

The authors would like to thank the participants of this study.

Authors' Contribution

Conceptualization: Reza Mohammadi, Hamid Pakmaneh.

Data curation: Reza Mohammadi, Hamid Pakmaneh, Morteza Hashemian, Abbas Poorjafari.

Formal analysis: Reza Mohammadi, Abbas Poorjafari.

Funding acquisition: Reza Mohammadi, Abbas Poorjafari.

Investigation: Reza Mohammadi, Hamid Pakmaneh, Morteza Hashemian, Abbas Poorjafari.

Methodology: Reza Mohammadi, Hamid Pakmaneh, Morteza Hashemian, Abbas Poorjafari.

Project administration: Reza Mohammadi, Hamid Pakmaneh.

Resources: Reza Mohammadi, Hamid Pakmaneh, Abbas Poorjafari.

Software: Abbas Poorjafari.

Supervision: Reza Mohammadi, Hamid Pakmaneh, Morteza Hashemian.

Validation: Reza Mohammadi.

Visualization: Reza Mohammadi, Hamid Pakmaneh.

Writing—original draft: Reza Mohammadi, Abbas Poorjafari, Hamid Pakmaneh.

Writing—review & editing: Morteza Hashemian, Abbas Poorjafari.

Competing Interests

The authors declare that there is no conflict of interest.

Ethical Approval

This study has been approved by the Ethics Committee of the Kerman University of Medical Sciences (IR.KMU.AH.REC.1398.091).

References

1. Kaufman DS, Shipley WU, Feldman AS. Bladder cancer. *Lancet*. 2009;374(9685):239-49. doi: [10.1016/s0140-6736\(09\)60491-8](https://doi.org/10.1016/s0140-6736(09)60491-8).
2. Lopez-Beltran A. Bladder cancer: clinical and pathological profile. *Scand J Urol Nephrol Suppl*. 2008(218):95-109. doi: [10.1080/03008880802325226](https://doi.org/10.1080/03008880802325226).
3. Partin AW, Dmochowski RR, Kavoussi LR, Peters CA, Wein AJ. *Campbell Walsh Urology, E-Book*: Elsevier Health Sciences; 2020.
4. Millán-Rodríguez F, Chéchile-Toniolo G, Salvador-Bayarri J, Palou J, Vicente-Rodríguez J. Multivariate analysis of the prognostic factors of primary superficial bladder cancer. *J Urol*. 2000;163(1):73-8. doi: [10.1016/s0022-5347\(05\)67975-x](https://doi.org/10.1016/s0022-5347(05)67975-x).
5. Compoj E, Dechet CB, Mian M, Trenti E, Palermo S, Lodde M, et al. Perforation during TUR of bladder tumours influences the natural history of superficial bladder cancer. *World J Urol*. 2014;32(5):1219-23. doi: [10.1007/s00345-013-1197-x](https://doi.org/10.1007/s00345-013-1197-x).
6. Miladi M, Peyromaure M, Zerbib M, Saïghi D, Debré B. The value of a second transurethral resection in evaluating patients with bladder tumours. *Eur Urol*. 2003;43(3):241-5. doi: [10.1016/s0302-2838\(03\)00040-x](https://doi.org/10.1016/s0302-2838(03)00040-x).
7. Dutta SC, Smith JA Jr, Shappell SB, Coffey CS, Chang SS, Cookson MS. Clinical under staging of high risk nonmuscle invasive urothelial carcinoma treated with radical cystectomy. *J Urol*. 2001;166(2):490-3. doi: [10.1016/s0022-5347\(05\)65969-1](https://doi.org/10.1016/s0022-5347(05)65969-1).
8. Chang SS, Boorjian SA, Chou R, Clark PE, Daneshmand S, Konety BR, et al. Diagnosis and treatment of non-muscle invasive bladder cancer: AUA/SUO guideline. *J Urol*. 2016;196(4):1021-9. doi: [10.1016/j.juro.2016.06.049](https://doi.org/10.1016/j.juro.2016.06.049).
9. Gaya JM, Palou J, Cosentino M, Patiño D, Rodríguez-Faba O, Villavicencio H. A second transurethral resection could be not necessary in all high grade non-muscle-invasive bladder tumors. *Actas Urol Esp (Engl Ed)*. 2012;36(9):539-44. doi: [10.1016/j.acuroe.2012.03.008](https://doi.org/10.1016/j.acuroe.2012.03.008).
10. Han KS, Joung JY, Cho KS, Seo HK, Chung J, Park WS, et al. Results of repeated transurethral resection for a second opinion in patients referred for nonmuscle invasive bladder cancer: the referral cancer center experience and review of the literature. *J Endourol*. 2008;22(12):2699-704. doi: [10.1089/end.2008.0281](https://doi.org/10.1089/end.2008.0281).
11. Gill TS, Das RK, Basu S, Dey RK, Mitra S. Predictive factors for residual tumor and tumor upstaging on relook transurethral resection of bladder tumor in non-muscle invasive bladder cancer. *Urol Ann*. 2014;6(4):305-8. doi: [10.4103/0974-7796.140990](https://doi.org/10.4103/0974-7796.140990).
12. El-Barky E, Sebaey A, Eltabey M, Aboutaleb A, Hussein S, Kehinde EO. The importance of second-look transurethral resection for superficial bladder cancer. *J Clin Urol*. 2015;8(5):299-305. doi: [10.1177/2051415814560189](https://doi.org/10.1177/2051415814560189).
13. Cumberbatch MGK, Foerster B, Catto JWF, Kamat AM, Kassouf W, Jubber I, et al. Repeat transurethral resection in non-muscle-invasive bladder cancer: a systematic review. *Eur Urol*. 2018;73(6):925-33. doi: [10.1016/j.eururo.2018.02.014](https://doi.org/10.1016/j.eururo.2018.02.014).
14. Dwivedi US, Kumar A, Das SK, Trivedi S, Kumar M, Sunder S, et al. Relook TURBT in superficial bladder cancer: its importance and its correlation with the tumor ploidy. *Urol Oncol*. 2009;27(5):514-9. doi: [10.1016/j.uroonc.2008.04.015](https://doi.org/10.1016/j.uroonc.2008.04.015).
15. Schwaibold HE, Sivalingam S, May F, Hartung R. The value of a second transurethral resection for T1 bladder cancer. *BJU Int*. 2006;97(6):1199-201. doi: [10.1111/j.1464-410X.2006.06144.x](https://doi.org/10.1111/j.1464-410X.2006.06144.x).
16. Naselli A, Hurler R, Paparella S, Buffi NM, Lughezzani G, Lista G, et al. Role of restaging transurethral resection for T1 non-muscle invasive bladder cancer: a systematic review and meta-analysis. *Eur Urol Focus*. 2018;4(4):558-67. doi: [10.1016/j.euf.2016.12.011](https://doi.org/10.1016/j.euf.2016.12.011).
17. Grimm MO, Steinhoff C, Simon X, Spiegelhalder P, Ackermann R, Vogeli TA. Effect of routine repeat transurethral resection for superficial bladder cancer: a long-term observational study. *J Urol*. 2003;170(2 Pt 1):433-7. doi: [10.1097/01.ju.0000070437.14275.e0](https://doi.org/10.1097/01.ju.0000070437.14275.e0).

© 2023 The Author(s); Published by Kerman University of Medical Sciences. This is an open-access article distributed under the terms of the Creative Commons Attribution License (<https://creativecommons.org/licenses/by/4.0/>), which permits unrestricted use, distribution, and reproduction in any medium, provided the original work is properly cited.