

A case Report of Cardiac Hydatid Cyst found during an Emergent Tamponade Surgery in an Unstable Patient

Behnam Askari, M.D. ¹, Kamal khademvatani, M.D. ², Hamid Mehdizade, M.D. ³, Roghie Babakan, M.D. ⁴

1-Assistant Professor, Department of Cardiovascular Surgery, Seyed-al-Shohada Heart Center, Urmia University of Medical Sciences, Urmia, Iran
(Corresponding author; askaribehnam@ymail.com)

2- Associate Professor, Department of Cardiology, Seyed-al-Shohada Heart Center, Urmia University of Medical Sciences, Urmia, Iran

3-Assistant Professor, Department of Cardiovascular Surgery, Seyed-al-Shohada Heart Center, Urmia University of Medical Sciences, Urmia, Iran

4- General Physician, Urmia University of Medical Sciences, Urmia, Iran

Received: 15 April, 2018

Accepted: 1 July, 2018

ARTICLE INFO

Article type:

Case Report

Keywords:

Acute cardiac tamponade

Hydatid cyst

Echinococcosis

Abstract

Cardiac hydatid cysts are uncommon and pericardial involvement is extremely uncommon.

We report a rare case of a cardiac hydatid cyst that was surprisingly found during an emergent tamponade surgery in a woman. She was pale, febrile, ill and toxic and 300cc turbid and purulent fluid was drained. In taking history, it was found that the patient had six sheep dogs in her house. Laboratory analysis revealed elevated C-reactive protein, elevated white blood cell count (neutrophil 80% and eosinophils less than 5%), anemia and negative immunoglobulin ELISA. Complete reevaluation revealed two relatively large hydatid cysts; the biggest one (5cm diameter) was in the lateral side of the left atrium and the other one (2.5cm diameter) was in the inferior of ascending aorta. Surgical removal of the cyst was performed via median sternotomy and cardiopulmonary bypass. The patient had pericarditis, fibrinous adhesions and heart inflammation. Postoperative period was uneventful and the patient received Albendazole for six months. There was no recurrence during the one- year follow-up period.

Copyright: 2018 The Author(s); Published by Kerman University of Medical Sciences. This is an open-access article distributed under the terms of the Creative Commons Attribution License (<http://creativecommons.org/licenses/by/4.0>), which permits unrestricted use, distribution, and reproduction in any medium, provided the original work is properly cited.

Citation: Askari B, khademvatani K, Mehdizade H, Babakan R. A case Report of Cardiac Hydatid Cyst found during an Emergent Tamponade Surgery in an Unstable Patient. Journal of Kerman University of Medical Sciences, 2018; 25 (6): 540-544.

Introduction

Hydatid disease is a zoonosis parasitic infection caused by *Echinococcus granulosus* and is endemic in many parts of the world, including Iran (1). Cardiac hydatidosis is an infrequent type of hydatidosis with 0.5% to 2% prevalence rate, in comparison to the liver (65%) and the lung (25%) (2). Pericardial involvement in cardiac hydatid cysts is extremely uncommon (3).

We report a case of cardiac hydatid cyst in a young woman referred with symptoms of severe dyspnea, palpitation and shock.

Case report

A 33 year-old, rural, married woman with no literacy referred to our hospital with nausea, chest pain and dyspnea (NYHA class 4) and low grade fever.

Her complaints had been started several weeks earlier and severely increased from one week prior to the admission. On physical examination she was pale and febrile. Her vital signs were:

blood pressure: 90/60 mmHg, heart rate: 128 beats/minute, respiratory rate: 28/minute and oral temperature: 38°C. Jugular veins were distended. General condition was ill, toxic and pre-arresting. On auscultation, heart sounds were muffled.

Chest X-ray revealed cardiomegaly. Electrocardiogram showed sinus tachycardia. Laboratory analysis revealed elevated erythrocyte sedimentation rate (ESR= 23 mm/h), C-reactive protein (CRP=76.5mg/L), white blood cell count: 11000/ μ l (neutrophil 80% and eosinophils less than 5%), hemoglobin: 10.8 g/dL and immunoglobulin ELISA (anti echinococcosis IgG) was negative. Transthoracic echocardiography demonstrated ejection fraction of 40% and large pericardial effusion with cardiac tamponade.

After emergent surgical consultation, due to tamponade, the patient was immediately transferred to the operation room and through subxiphoid approach, 300cc exudative fluid was drained. The fluid appearance was turbid and purulent. Surprisingly, we saw one large already ruptured cystic mass (5*3.5*1.5) and multiple small cysts that were suspicious to hydatid cysts (Figure1). Immediately following drainage, systole blood pressure increased from 60 mmHg to 110 mmHg.

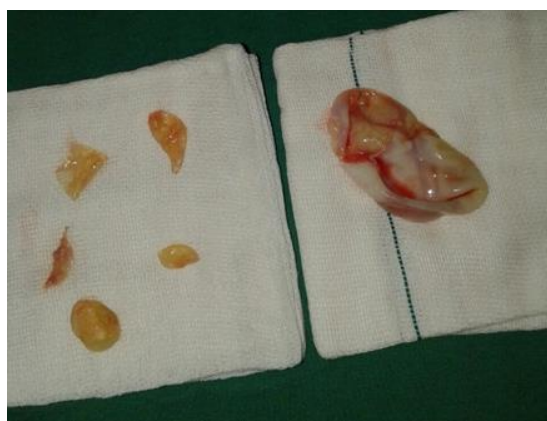

Figure 1. Multiple hydatid cysts

After tamponade surgery, complete reevaluation was done. Later, it was found that the patient and her family had six sheep dogs in their house. Repeated echocardiography (transthoracic and transesophageal) confirmed persistent cystic mass inside the pericardial cavity. There were two relatively large hydatid cysts; the biggest one (5cm diameter) was in the lateral side of the left atrium, and the other one (2.5cm diameter) was in the inferior of the ascending aorta (Figure2).

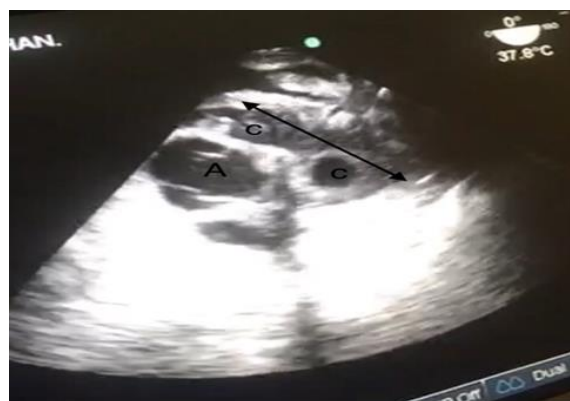

Figure2. Transesophageal Echocardiography
two large cysts (c) in the posterior of aorta (A)

Pericardial effusion analysis showed many leukocytes (polymorphonuclear), but fluid culture was negative. In pathological analysis of the specimen, the diagnosis of hydatid cysts was confirmed by gross observation and the written report of the pathologist. Consultation with infectious diseases

specialist was done and oral albendazole (400 mg/ twice a day) was started. A computed tomography (CT) scan of the chest and abdominal ultrasonography revealed no cysts in the lungs and liver.

The patient underwent the second surgery. Median sternotomy was performed and thick pericardium (5mm) was opened. There were pericarditis and fibrinous adhesions and heart inflammation. Cardiopulmonary bypass (CPB) was instituted using bicaval and ascending aorta cannulation. After ascending aorta cross-clamping and infusion of cold ante grade crystalloid cardioplegic solution, cardiac arrest was achieved. There were multiple hydatid cysts; some of those were ruptured and non-fertile and other cysts were intact and fertile. Location of cysts were in behind of the ascending aorta and the other intact cyst was subepicardially close to the left atrial auricle and left circumflex coronary (LCX) artery with thick wall. All cysts were removed, pericystectomy was done and their cavities were cleansed and sterilized with hypertonic saline solution. Total aortic cross clamp time was 36 minutes and Cardiopulmonary bypass time was 109 minutes (figures 3, 4).

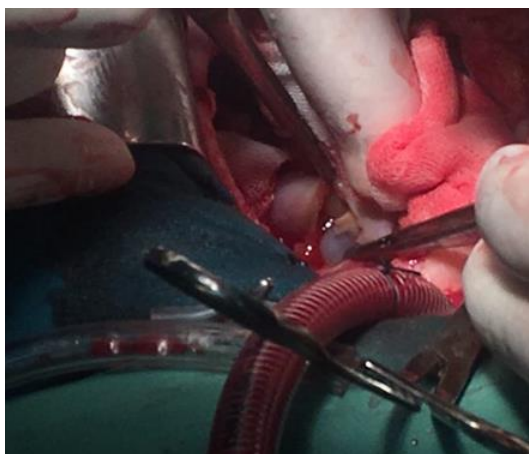


Figure 2. Intraoperative view of intact cysts

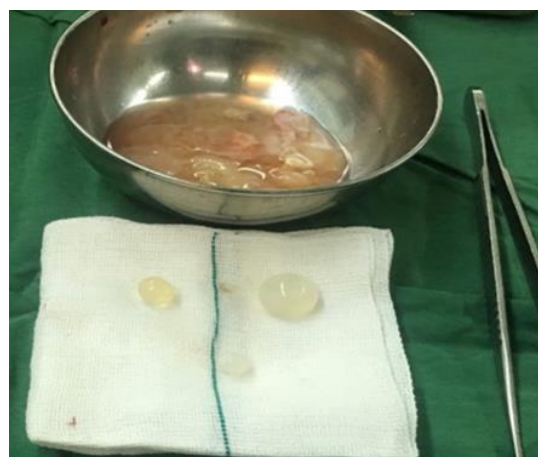

Figure 3. multiple ruptured and intact hydatid cysts

The patient had an uneventful postoperative course and was discharged on the 6th post-operative day. Albendazole treatment that had been started one week preoperatively was continued for six months postoperatively. The patient was asymptomatic and there was no recurrence in serial echocardiographic evaluation during the one year follow-up period.

Discussion

Human hydatidosis is more frequent in rural regions and in female individuals (4). In one of the previous studies, 12.5% of the dogs in West Azerbaijan / Iran were infected with *Echinococcus granulosus*, while golden jackal and red fox did not have a major role in epidemiology, due to different geographical and environmental situation (5). The presented case was a rural woman who kept six sheep dogs in her house. Symptoms depend on the location, size, compression or involvement of the adjacent structures and the presence of complications (6). After intracranial and musculoskeletal, the third most common unusual location of the hydatid cyst reported from Iran is the cardiovascular system, accounting for 42 reported cases during the last 20 years. Most of the cardiac hydatid cysts were located in the ventricular wall. Some less

frequent symptoms related to pericardial tamponade have also been reported (1).

Hydatid cysts of the LV are usually located subepicardially and are rarely ruptured into the pericardial space. However, when it happens, rupture may be silent, or it may cause acute pericardial tamponade, secondary pericardial cysts, or constructive pericarditis (7). In our case, there were subepicardially located Hydatid cysts and cardiac tamponade due to ruptured cysts with similar symptoms. Moreover, the most dangerous complication of cardiac echinococcosis is cyst perforation. After cyst perforation, three quarters of the patients die from septic shock or embolic complications (8, 9).

In most rarely reported cases of pericardial tamponade due to ruptured cardiac hydatid cysts, the fluid quality of pericardial effusion had been serous. In our case, fluid was turbid and purulent and had many leukocytes. In search of literature, we did not find similar fluid quality unless in one case that was an 81 year old female presented with purulent cardiac tamponade secondary to a hydatid cyst-associated hepatic abscess (10).

Serologic tests are often useful but some patients with echinococcosis do not develop a detectable immune response

(11). Our patient, despite her progressive disease, had negative immunoglobulin ELISA -anti echinococcosis IgG. Leukocyte count and ESR were not remarkable. There was Only CRP elevation.

Benzimidazole, alone, is contraindicated in large cysts with the risk of rupture and it is recommended to reduce the risk of recurrence after the surgery. Albendazole is administered in several 1-month oral doses (10-15 mg/kg/d) separated by 14 days intervals.

The optimal period of treatment ranges from 3-6 months. Monitoring of patients for adverse effects of medicines accompanied with evaluations of CBC count and liver function tests is necessary (12). In our case, postoperative albendazole treatment for six months was without any problems.

In Conclusion, cardiac hydatid cyst should be considered in the differential diagnosis of tamponade and intra-pericardial mass, especially in endemic areas. In patients presented with acute symptoms of pericardial tamponade, emergent pericardial drainage decreases the urgency of a definitive treatment of hydatid cysts.

References

1. Geramizadeh B. Unusual locations of the hydatid cyst: a review from Iran. *Iran J Med Sci* 2013; 38(1):2-14.
2. Hosseinian A, Mohammadzadeh A, Shahmohammadi G, Hasanpour M, Maleki N, Doustkani H, et al. Rupture of a giant cardiac hydatid cyst in the left ventricular free wall: successful surgical management of a rare entity. *Am J Cardiovasc Dis* 2013; 3(2): 103-6.
3. Kosecik M, Karaoglanoglu M, Yamak B. Pericardial hydatid cyst presenting with cardiac tamponade. *Can J Cardiol* 2006; 22(2): 145-7.
4. Khalkhali HR, Foroutan M, Khademvatan S, Majidiani H, Aryamand S, Khezri P, et al. Prevalence of cystic echinococcosis in Iran: a systematic review and meta-analysis. *J Helminthol* 2018; 92(3):260-8.

5. Dalimi A, Motamedi G, Hosseini M, Mohammadian B, Malaki H, Ghamari Z, et al. Echinococcosis/hydatidosis in western Iran. *Vet Parasitol* 2002; 105(2):161-71.
6. Bogdanovic A, Radojkovic M, Tomasevic RJ, Pesic I, Petkovic TR, Kovacevic P, et al. Presentation of pericardial hydatid cyst as acute cardiac tamponade. *Asian J Surg* 2017; 40(2):175-7.
7. Tuncer E, Tas SG, Mataraci I, Tuncer A, Donmez AA, Aksut M, et al. Surgical treatment of cardiac hydatid disease in 13 patients. *Tex Heart Inst J* 2010; 37(2): 189–93.
8. Ohri S, Sachdeva A, Bhatia M, Shrivastava S. Cardiac hydatid cyst in left ventricular free wall. *Echo Res Pract* 2015; 2(1):K17-9.
9. Shojaei E, Yassin Z, Reza Hosseini O. Cardiac hydatid cyst: a case report. *Iran J Public Health* 2016; 45(11): 1507–10.
10. Lainez B, Ruiz V, Berjón J, Lezaun R. Purulent pericarditis complicated by cardiac tamponade secondary to a hydatid cyst-associated hepatic abscess. *Rev Esp Cardiol* 2009; 62(8):941-54.
11. Fazlinezhad A, Moohebbati M, Azari A, Bigdeloo L. Acute pericardial tamponade due to ruptured multiloculated myocardial hydatid cys. *European Journal of Echocardiography* 2009; 10(3): 459–61.
12. Dandan IS, Anand BS, Soweid AM, Abiad F, Talavera F, Ouyang A. Hydatid cysts treatment & management. *Medscape*; 2017 [cited 2016 Sep 12]. Available from: <https://emedicine.medscape.com/article/178648-treatment>