

The Effect of Varicocelelectomy on Assisted Reproductive Technique Indications and Outcomes based on Kruger Strict Morphology Test: a Randomized Clinical Trial

Ali Asghar Ketabchi, M.D. ¹, Sohrab Mohammad Salehi, M.D. ², Shirin Salajghah, M.D. ³

1- Associate Professor of Urology, Physiology Research Center, Kerman Medical Sciences University, Kerman, Iran (Corresponding author; E-mail: mrketabchi@yahoo.com)

2- Urology Resident, Kerman Medical Sciences University, Kerman, Iran

3- Anesthesia Department, Physiology Research Center, Kerman Medical Sciences University, Kerman, Iran

Received: 1 October, 2018

Accepted: 7 November, 2018

ARTICLE INFO

Article type:
Original Article

Keywords:

Varicocele
Semen Analysis
Assisted reproductive techniques
Kruger strict morphology test

Abstract

Background: A significant percent of infertile varicocele patients remained infertile after varicocelelectomy and finally most of them refer for assisted reproductive technique (ART) procedures as intra uterine insemination (IUI), in vitro fertilization (IVF) and intracytoplasmic sperm injection (ICSI). In order to achieve the best results, more strict and accurate standards for assessment of sperm parameters, as Kruger standards, are required.

Objective: The main goal of this study was to evaluate the efficacy of varicocelelectomy on improving selection of ARTs on the base of Kruger strict morphology test.

Method: In a randomized clinical trial study, the results of sperm parameters analysis by Kruger strict morphology test were compared between a group of 67 infertile operated patients and a group of 71 matched no operated men in one-year duration.

Results: The selection of better ART levels (IUI vs. ICSI) after varicocelelectomy was higher in the operated group than controls ($p < 0.05$). Pregnancy rates (achieving full-term pregnancy by natural cycle intercourse), after one year, were respectively 53.84% and 42.25% in the two groups of operated and non-operated ($p = 0.082$).

Conclusion: According to our results, varicocelelectomy improves the ART level selection and also may improve pregnancy success rates (both by natural cycle intercourse and ART procedures).

Copyright: 2018 The Author(s); Published by Kerman University of Medical Sciences. This is an open-access article distributed under the terms of the Creative Commons Attribution License (<http://creativecommons.org/licenses/by/4.0>), which permits unrestricted use, distribution, and reproduction in any medium, provided the original work is properly cited.

Citation: Ketabchi A.A, Mohammad Salehi S, Salajghah SH. The Effect of Varicocelelectomy on Assisted Reproductive Technique Indications and Outcomes based on Kruger Strict Morphology Test: a Randomized Clinical Trial. Journal of Kerman University of Medical Sciences, 2018; 25 (6): 519-527.

Introduction

Varicocele is an abnormal dilatation of the pampiniform venous plexus and occurs secondary to retrograde flow via the internal spermatic vein, due to incompetent or absent valves (1). Most Varicoceles are developed on the left side because the left testicular vein is longer than the right internal spermatic vein and also enters the left renal vein at a right angle. In addition, sometimes the “nutcracker phenomenon” has been observed in left varicoceles. The left renal vein is located between the descending aorta and the superior mesenteric artery. This increases left testicular vein pressure by compressing the renal vein. Varicoceles occur with an incidence of 15% in adolescent males and 10–15% in adult men and overall, it is present between 4.4% - 22.6% in the general male population (1-3). About 35%– 40% of men seeking infertility treatment are affected (4). Physical examination is the base of diagnosing varicoceles, but the introduction of ultrasound and radiographic diagnostic methods has been resulted in improved detection and further characterization of varicoceles (5). In most studies performed in recent decades, an association between the presence of varicocele and semen parameter abnormalities in infertile men has been observed (6, 7). MacLeod, in 1965, for the first time, observed that the majority of infertile men with clinical varicocele had lower sperm count, decreased motility, and more frequent abnormal sperm morphologies in their semen analysis compared to fertile men (8). According to World Health Organization (WHO), the prevalence of varicocele is 25.4% among infertile men with abnormal semen; this report noted that varicocele is accompanied

with decreased testicular volume, lower indices of sperm function and reduced Leydig cell function. Moreover, clinical varicoceles affect epididymal functions and might also disturb vas deferens mobility (9-11).

Although, today, varicocelectomy is widely used as a treatment for male infertility, there are some studies on infertile men with and without varicocele that have not shown any significant difference between sperm parameters, such as count, motility, and shape; so, the efficacy of varicocelectomy has been still debated for about 50 years. (12-14). The ultimate goal of varicocelectomy is increasing pregnancy rate and enhancing the couple’s fertility potential through improving sperm quality or prevention of further testicular function decline (15). Apart from the basic known pathogenesis of varicocele, due to non-uniform risk factors among patients, as genetic factors, antioxidants effects, individual physical conditions, environmental effects and many other known and unknown factors, varicocele has multi-factorial pathogenesis (16). It seems that the multiplicity of these factors makes the outcome of the varicocelectomy unpredictable and even leads to poor results; therefore, accurate diagnosis and deletion of the involved factors can improve the operation results. On the other hand, a great portion of varicocele patients remain infertile after the operation and inevitably refer for assisted reproductive technique (ART) processes. It is natural that higher qualities of semen parameters causes better results in ARTs (17). At present, the suggested indications for ARTs include decreased semen quality and some female infertility causes such as cervical

factors, unexplained infertility, the role of anti-sperm antibodies and ejaculatory abnormalities. In the absence of female factors, the selection of intrauterine insemination (IUI) versus intracytoplasmic sperm injection (ICSI), as the best ART, is usually done according to semen parameter qualities (18). The best and most simple type of ARTs is IUI, that has been used since 1921 and was explained by Dickinson on the 45th Annual Meeting of the American Gynecological Society in Chicago (19) and then, rapid developments, like introduction of in vitro fertilization (IVF) and ICSI, occurred in this field (19). IUI is the primary step of ART and compared to other steps, it has less cost and complications such as surgical risks associated with egg removal and risks of embryonic abnormalities following IVF, ICSI or egg donation. In opposite, ICSI procedure is more time consuming for ART staffs and imposes extra expense on the infertile couple. Also, recent studies have not shown the superiority of ICSI to conventional IVF in terms of embryo quality or clinical pregnancy rate (20, 21). Therefore, in order to achieve better results in varicocelectomy and even in the choice of ART procedures, it is necessary to recognize and treat the known effective co-factors in the improvement of sperm parameters and natural pregnancy. Modification of the mentioned co-factors will also be effective in the results of varicocelectomy. Our aim in this study was to achieve predictable points of the selection criteria according to Kruger strict morphology test by investigating varicocelectomy effects on semen parameters to identify ART categories between the two groups of varicocelectomy patients and no operated patients.

Material and Methods

In this randomized clinical trial, 255 infertile clinical varicocele patients (left side with at least one main semen parameter abnormality except isolated teratozoospermia), whose spouses were 35 years old or younger) were selected. Patients with bilateral varicoceles, recurrent varicoceles, operation complication (large hydroceles, testis atrophy, or those with history of risk factors such as addiction, exposure to cytotoxic agents, using hormonal medicine and having hyper-thermal job environments) were excluded. After obtaining informed consent, they were randomly (by Random allocation rule) divided into the experimental group (underwent sub inguinal microscopical varicocelectomy) and control group (did not undergo any treatment). The diagnosis of their disease was performed, initially, by clinical examination (in a private warm room at standing position with and without Valsalva maneuver) and confirmed by color Doppler ultrasound (if necessary). Prior to the intervention, two semen analyses, with two weeks interval, were done for both groups and results were recorded according to the 5th edition of WHO standards. Then, subjects in the experimental group were operated through sub inguinal approach with magnification by one surgeon (the author), The patients and their semen tests were evaluated in 3, 6 and 12 post-operative months according to ARTs selection criteria by Kruger strict morphology test (>15 Million sperms/ml for IUI, 514 Million sperms/ml for IVF and <04 Million sperms /ml for ICSI with $\geq 4\%$ normal morphology and progressive motility) (17).

Ethical registration

This study had been approved by the Ethics Committee of Physiology Research Center, Kerman University of Medical Sciences (Ref. number: IR. Kmu. REC. 1396. 03). All participants signed an informed consent for participation in this study. (Registration ID in IRCT: IRCT201611091981N7)

Statistical analysis

The results of semen parameters, complications, and pregnancy rates were analyzed through using SPSS-19 software and presented as percent and mean±SD, before and after the varicocelectomy. Mann–Whitney rank sum test and χ^2 test were used for comparison of two groups and $p < 0.05$ was considered as statistically significant level.

Results

From a large cohort study on 523 consecutive male factor infertility referrers, we identified 255 men with

clinical varicocele (186 ones (72.95%) grade III and 69 ones (27.05%) grade II, with matched grade ratio between the two groups) and abnormal sperm analysis. Finally, 136 men were selected and divided into the varicocelectomy or experimental group with 65 patients (47.79%) and non-operation or control group with 71 patients (52.21%). Mean age of subjects was 24 ± 3.7 years in the varicocelectomy group and 26 ± 2.8 years in the control group. The distribution of varicocele grades was not significantly different between the two groups. The pregnancy outcome and sperm analysis data according to the selected ARTs were determined before and one year after the study in both groups. In the experimental group, there were significant differences in sperm parameters before and after the study (Table 1&2), but pregnancy rate did not show significant difference. Sperm parameters analysis, after one year, according to the selected ARTs criteria have been presented for the experimental and control groups in table 3.

Table 1. Comparison of sperm analysis in the varicocelectomy group before and 3-12 months after the operation

varicocelectomy Group	Sperm count (* 10 ⁶)	Progressive motility %	Normal morphology %
After	37±2.6	45±4.7	24±5.6
Before	18±6.2	10± 3.2	5 ±4.4
P-value	<0.05	<0. 05	<0.05

Data presented as mean±SD. Mann–Whitney and t-test, p-value <0. 05: significant

Table 2. Comparison of sperm analysis in both groups after 3 months

Groups	Sperm count (* 10 ⁶)	Progressive motility%	Normal morphology%
varicocelectomy	37±2.6	45±4.7	24±5. 6
Control	15±5.5	12± 3.2	7 ±2. 2
P-value	<0. 05	<0. 05	<0. 05

Data presented as mean±SD.

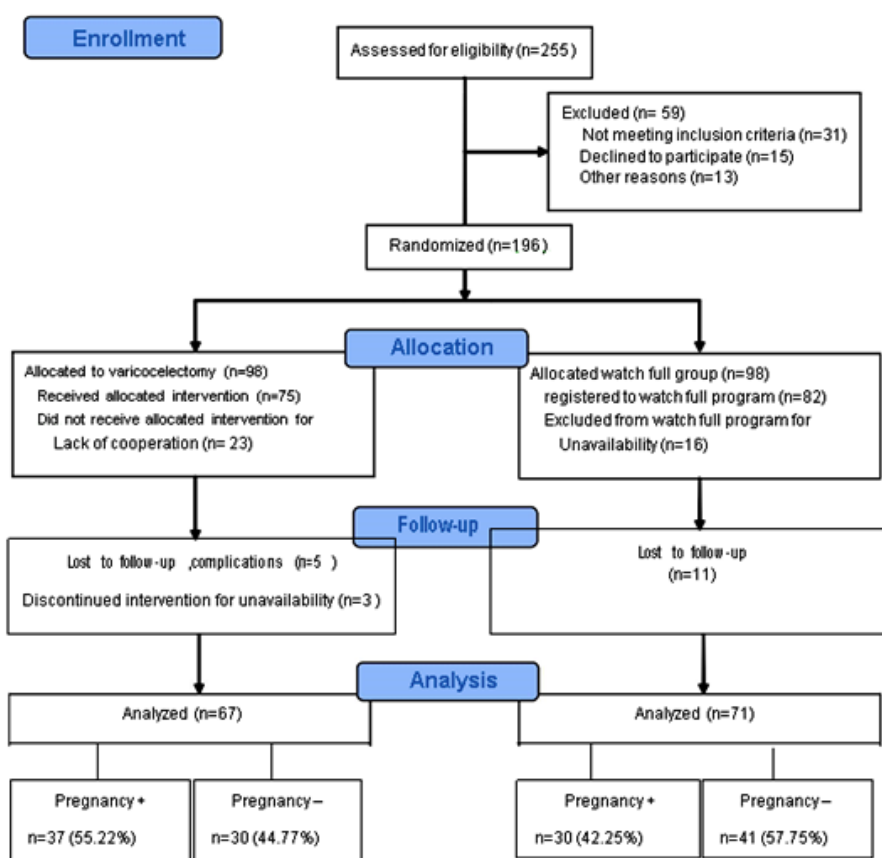
Mann–Whitney and t-test, p-value<0. 05: significant

Table 3. Comparison of sperm analysis in both groups after one year according to the selected ART

Groups	IUI (15< Million/ml)	IVF (5-14 Million/ml)	ICSI (4-0 Million/ml)
varicoceleotomy	30 (46.15%)	11 (16.92%)	24 (36.92%)
control	10 (14.08%)	15 (21.12%)	46 (64.78%)
P-value	<0. 001	P= 244	<0. 05

Data presented as number (percent).

Mann–Whitney test, value <0. 05 significant

**Figure 1.** Flow Diagram of pregnancy rate comparison between varicoceleotomy and watch full groups

Discussion

The human semen is declining in quantity and quality; although it may be attributed to changes in the population and be defined as normal, semen tests might explain these changes (22). The important change in what is considered normal is the morphology of sperms.

In fact, earlier editions of WHO criteria expected a higher percent for a sample to be called normal. WHO criteria have been changed from 80.5% cut off or greater as normal for ejaculate in the 1980 ed. to at least 4% in the 2010 ed. (18).

In fact, the 4% cut-off is the result of scientific and serious research of TF Kruger and R Menkeveld at Tygerberg Hospital in South Africa (20). The scientific validity of this ranking is based on the exact observation of the standard sperm morphology that conforms to the sperm of men who have been pregnant his wives for less than a year. So, it is necessary to reassess alternative treatments in infertility fields and their predictive roles in outcomes according to natural changes and strict measures and also it seems that sperm shape may correlate with a man's fertility potential, but in some studies it has been shown that it only correlates with the ability of sperm to penetrate and fertilize eggs in the setting of IVF (18).

Now, the best option after varicocelectomy is ART for the treatment of infertile men with clinical varicocele, especially if their spouses are older than 35 years old (23).

According to the mentioned points, among all semen parameters, the strict morphology is now known to be of strong prognostic value; therefore, in this controlled study, we have tried to find the real place of ARTs in the treatment of infertile varicocele patients by applying strict morphology testes of Kruger (24).

In our study, the natural pregnancy rate after one year was 42.25% in the control group and 53.84% after varicocele repair, with an odds ratio of 1.5944 (95% CI: from 0.8094-3.1406, $p=0.455$). In Abdel-Meguid et al. randomized study on 145 men with clinical varicoceles, after microsurgical varicocelectomy, the natural pregnancy rate was 32.9% in the operated group vs. 13.9% observed arm (in flow chart) (25). The natural

course of fertility in our patients are not different significantly than observation alone. Many factors may affect pregnancy rates after varicocele repair including the quality of sperm parameters before the treatment, patient characteristics, age of patient's wife, and also the repair duration. Therefore, our results may be due to different factors such as short duration of this study, sample size, follow-up duration, or even our patient selection methods (26), but finally, by applying Kruger strict morphology tests on patients' semen in the varicocelectomy group and the control group, sperm morphology indices were improved for selection of ARTs stages. This finding was similar to the results of some other studies such as Yusuf Kibar et al (27).

The rates of IUI and IVF selections, both were significantly higher in the operated group compared to the control group. In addition significant improvement in sperm morphology and the improvement of other main semen variables (sperm concentration and motility) not only maximize the couple's fertility potential for natural pregnancy, but also it qualified the chance of better ARTs results, that was compatible with the results of Esteves et al study. They compared intracytoplasmic sperm injection results between a group of 80 prior varicocele repaired patients and a group of 162 untreated varicoceles. The live birth rate was higher in the couples who had varicocele repair compared to the untreated group (46.2% vs. 31.4%, $p=0.03$) (28). Today, there is still debate and controversy about the effect of varicocelectomy on the natural course of fertility (29). Some studies have shown that varicocelectomy causes a significant

improvement in semen parameters which is in line with the results of our study (30). While the others suggested that these positive changes in semen variables might be due to time lapse and spontaneous disappearing of some affecting risk factors, as in our study, that we recommended both groups to avoid some known risk factors.

The use of ARTs is the final and best way for all couples that have fertility problems especially those with male factors. Unfortunately, the success rate of ARTs is not high and in addition these processes have often major complications and are relatively expensive as the stage changes from IUI to ICSI. Besides these problems, sperm indices have significant roles and the better semen parameters require lower ARTs stages (from ICSI to IUI). On the other hand, immediate ART treatment for these patients is more expensive than varicocelectomy (31)

Schlegel in 1997 denied the cost per successful that primary treatment with varicocelectomy was the more cost-effective approach, rather than sperm retrieval/ICSI. In a report in USA The mean cost of delivery with ICSI to be \$89,091 (95% CI, \$78,720 to

\$99,462), whereas the cost per successful delivery after varicocele repair was \$26,268 (95% CI, \$19,138 to \$44,646). Also, the benefit of varicocelectomy vs. ART procedures that are temporary and per request, is permanent (31,32). So, before the choice of ART types, it is recommended to qualify the semen parameters if possible.

Conclusion

As we showed in this study, the repair of varicoceles can be useful at least in unsuccessful varicocele repaired cases that refer for ARTs. It helps in selecting better stage or less invasive modalities of ARTs that are more cost benefit and lead to better results.

Acknowledgments

The author wishes to thank Urology Department personnel for their kind cooperation.

Conflict of interest

There is no conflict of interest.

References

1. Belay RE, Huang GO, Shen JK, Ko EY. Diagnosis of clinical and subclinical varicocele: how has it evolved? *Asian J Androl* 2016; 18 (2):182-5.
2. Kimura M, Nagao K. Role of varicocele repair for male infertility in the era of assisted reproductive technologies. *Reprod Med Biol* 2014; 13 (4):185-92.
3. Ketabchi AA, Salajegheh S. The effects of acupuncture treatment in infertile patients with clinical varicocele. *Nephro-Urology Monthly* 2018; 10 (6):e65451.
4. Masson P, Brannigan RE. The varicocele. *Urol Clin North Am* 2014; 41 (1):129-44.
5. Pauroso S, Di Leo N, Fulle I, Di Segni M, Alessi S, Maggini E. Varicocele: ultrasonographic

- assessment in daily clinical practice. *J Ultrasound* 2011; 14 (4):199-204.
6. Sinanoglu O, Eyyupoglu SE, Ekici S. Ipsilateral testicular catchup growth rate following microsurgical inguinal adolescent varicocelectomy. *The Scientific World Journal* 2012; 2012:356374.
 7. Agarwal A, Sharma R, Harlev A, Esteves SC. Effect of varicocele on semen characteristics according to the new 2010 World Health Organization criteria: a systematic review and meta-analysis. *Asian J Androl.* 2016;18 (2):163-70.
 8. Santana VP, Miranda-Furtado CL, de Oliveira-Gennaro FG, Dos Reis RM. Genetics and epigenetics of varicocele pathophysiology: an overview. *J Assist Reprod Genet.* 2017;34 (7):839-847. Kantartzi PD, Goulis Ch, Goulis GD, Papadimas I. Male infertility and varicocele: myths and reality. *Hippokratia* 2007; 11 (3):99-104.
 9. Demirtola A, Ozen IO, Ozturk GS, Vural IM, Ercan S, Kale N, et al. The effects of varicocele and its surgical correction on vas deferens motility. *Pediatr Surg Int* 2008; 24 (3):319-23.
 10. Zhang QY, Qiu SD, Ma XN, Yu HM, Wu YW. Effect of experimental varicocele on structure and function of epididymis in adolescent rats. *Asian J Androl* 2003; 5 (2):108-12.
 11. Will MA, Swain J, Fode M, Sonksen J, Christman GM, Ohl D. The great debate: varicocele treatment and impact on fertility. *Fertil Steril* 2010; 95 (3):841-52.
 12. Lipshultz LI, Corriere JN Jr. Progressive testicular atrophy in the varicocele patient. *J Urol* 1977; 117 (2):175-6.
 13. Fariss BL, Fenner DK, Plymate SR, Brannen GE, Jacob WH, Thomason AM. Seminal characteristics in the presence of a varicocele as compared with those of expectant fathers and prevasectomy men. *Fertil Steril* 1981; 35 (3):325-7.
 14. Chen SS, Chen LK. Predictive factors of successful varicocelectomy in infertile patients. *Urol Int* 2011; 86 (3):320-4.
 15. Baazeem A, Belzile E, Ciampi A, Dohle G, Jarvi K, Salonia A, et al. varicocele and male factor infertility treatment: a new metaanalysis and review of the role of varicocele repair. *Eur Urol* 2011; 60 (4):796-808.
 16. Mohamed EE, Gawish M, Mohamed A. Semen parameters and pregnancy rates after microsurgical varicocelectomy in primary versus secondary infertile men. *Human Fertility* 2017; 20 (4):293-6.
 17. Mangoli V, Dandekar S, Desai S, Mangoli R. The outcome of ART in males with impaired spermatogenesis. *J Hum Reprod Sci* 2008; 1 (2):73-6.
 18. Keck C, Gerber-Schäfer C, Breckwoldt M. Intrauterine insemination as first line treatment of unexplained and male factor infertility. *European Journal of bstetrics & Gynecology and Reproductive Biology* 1998; 79 (2):193-7.
 19. Fang C, Tang J, Huang R, Li LL, Zhang MF, Liang XY. Comparison of IVF outcomes using conventional insemination and ICSI in ovarian cycles in which only one or two oocytes are obtained. *J Gynecol Obstet Biol Reprod (Paris)* 2012; 41 (7):650-6.
 20. Menkveld R. Clinical significance of the low normal sperm morphology value as proposed in the fifth edition of the WHO Laboratory Manual

- for the Examination and Processing of Human Semen. *Asian J Androl* 2010; 12:47–58.
21. Check JH, Bollendorf A, Wilson C, Summers-Chase D, Horwath D, Yuan W. A retrospective comparison of pregnancy outcome following conventional oocyte insemination vs intracytoplasmic sperm injection for isolated abnormalities in sperm morphology using strict criteria. *J Androl* 2007; 28 (4):607-12.
 22. Sengupta P. Reviewing reports of semen volume and male aging of last 33 years: From 1980 through 2013. *Asian pac j reprod* 2015; 4 (3):242-6.
 23. O'Brien JH, Bowles B, Kamal KM, Jarvi K, Zini A. Microsurgical varicocele for infertile couples with advanced female age: natural history in the era of ART. *J Androl* 2004; 25 (6):939-43.
 24. Cho KS, Seo JT. Effect of varicocele on male infertility. *Korean J Urol* 2014; 55 (11):703-9.
 25. Abdel-Meguid TA, Al-Sayyad A, Tayib A, Farsi HM. Does varicocele repair improve male infertility? an evidence-based perspective from a randomized, controlled trial. *Eur Urol* 2011; 59 (3):455-61.
 26. Al-Ghazo MA, Ghalayini IF, al-Azab RS, Bani-Hani I, Daradkeh MS. Does the duration of infertility affect semen parameters and pregnancy rate after varicocele? a retrospective study. *Int Braz J Urol* 2011; 37 (6):745-50.
 27. Kibar Y, Seckin B, Erduran D. The effects of subinguinal varicocele on kruger morphology and semen parameters. *J Urol* 2002; 168 (3):1071-4.
 28. Esteves SC, Oliveira FV, Bertolla RP. Clinical outcome of intracytoplasmic sperm injection in infertile men with treated and untreated clinical varicocele. *J Urol* 2010; 184 (4):1442-6.
 29. Nistal M, González-Peramato P, Serrano A, Regadera J. Physiopathology of the infertile testicle. Etiopathogenesis of varicocele. *Arch Esp Urol* 2004; 57 (9):883-904. [In Spanish].
 30. Miyaoka R, Esteves SC. A critical appraisal of the role of varicocele in male infertility. *Adv Urol* 2012; 2012:597495.
 31. Werthman P, Wixon R, Kasperon K, Evenson DP. Significant decrease in sperm deoxyribonucleic acid fragmentation after varicocele. *Fertil Steril* 2008; 90 (5):1800-4.
 32. Schlegel PN. Is assisted reproductive the optimal treatment for varicocele-associated male infertility? A cost-effectiveness analysis. *Urology* 1997; 49:83–90.