

## CBCT Findings in Different Types of Temporomandibular Joint Ankylosis

Mahrokh Imanimoghaddam, M.Sc.<sup>1</sup>, Seyed Hosein Hoseini-Zarch, M.Sc.<sup>2</sup>, Amin Rahpeyma, M.Sc.<sup>3</sup>, Nasim Khaki, M.Sc.<sup>4</sup>,  
Shahin Moeini, D.D.S.<sup>5</sup>

1- Professor, Department of Oral and Maxillofacial Radiology, School of Dentistry, Mashhad University of Medical Sciences, Mashhad, Iran  
2- Associate Professor, Department of Oral and Maxillofacial Radiology, School of Dentistry, Mashhad University of Medical Sciences, Mashhad, Iran  
3- Oral and Maxillofacial Diseases Research Center, Mashhad University of Medical Sciences, Mashhad, Iran  
4- Assistant Professor, Department of Maxillofacial Radiology, Faculty of Dentistry, Guilan University of Medical Sciences Dental School, Guilan, Iran  
5- Post Graduate Student, Department of Oral and Maxillofacial Radiology, School of Dentistry, Mashhad University of Medical Sciences, Mashhad, Iran (Corresponding author: Email: Moinish971@mums.ac.ir)  
Received: 16 April, 2020 Accepted: 5 September, 2020

### ARTICLE INFO

#### Article type:

Original Article

#### Keywords:

Temporomandibular joint  
Ankylosis  
Cone beam computed tomography

### Abstract

**Background:** Ankylosis of temporomandibular joint describes the pathological development of bony connections or fibrosis that occurs in the region between the condylar head of the mandible and the glenoid fossa of the temporal bone. This condition can severely affect the function of temporomandibular joint and its mobility. The aim of this study was to evaluate the practicality of CBCT imaging in different types of temporomandibular joint ankylosis.

**Methods:** This cross-sectional study involved 32 cases of ankylosed temporomandibular joint from 26 patients (12 males and 14 females) aged 8-65 years (mean age: 29.8±14.3) who had visited a private maxillofacial clinic between 2013 and 2016 for CBCT images of temporomandibular joint and had been diagnosed with ankylosis by a maxillofacial surgeon. The present study relied on both Dongmei's and Sawhney's classifications to assess the different types of joint ankylosis. A number of morphological parameters, including: D1 (the mediolateral diameter of the condyle), D2 (the width of the bony fusion area), D3 (the degree of calcification in the bony fusion area) and D4 (the D2/D1 ratio) were also defined and registered.

**Results:** All of the four variables (D1, D2, D2/D1 and D4) showed a negative correlation with the extent of mouth opening, but the amounts were non-significant ( $P>0.05$ ). The level of agreement between the two classification approaches was significantly low ( $P=0.003$ ). The highest degree of coronoid hyperplasia was seen in types II and III according to both Sawhney's and Dongmei's classifications. The greatest measure of condylar head displacement was observed in types II and III of Sawhney's, and type III of Dongmei's classification. Connection in the lateral side of the joint in type III of both Sawhney's and Dongmei's classifications was the most frequent case. More severe cases of ankylosis were commonly associated with older ages, but the relationship was not significant ( $P>0.05$ ).

**Conclusions:** CBCT seems to be the most advantageous modality of imaging as far as temporomandibular joint abnormalities are concerned, including ankylosis. Although the application of the two conventional classifications (Sawhney's and Dongmei's) produced little agreement in terms of radiological findings, it seems that the employment of such classifications in conjunction with CBCT imaging is a promising method for the diagnosis and evaluation of temporomandibular joint ankylosis.

**Copyright:** 2020 The Author(s); Published by Kerman University of Medical Sciences. This is an open-access article distributed under the terms of the Creative Commons Attribution License (<http://creativecommons.org/licenses/by/4.0>), which permits unrestricted use, distribution, and reproduction in any medium, provided the original work is properly cited.

**Citation:** Imanimoghaddam M, Hoseini-Zarch S.H, Rahpeyma A, Khaki N, Moeini S.H. CBCT Findings in Different Types of Temporomandibular Joint Ankylosis. *Journal of Kerman University of Medical Sciences*, 2020; 27 (6): 553-568

## Introduction

The temporomandibular joint (TMJ) is one of the most complicated joints in the human body due to its particular anatomy and function (1).

The term TMJ ankylosis is used to refer to the pathological development of bony connections or fibrosis in this joint, which seriously impairs its function and mobility. These connections can occur between the condylar head of the mandible and the glenoid fossa of the temporal bone, or between the certain tissues of the mandible (soft / hard) and the maxilla, the zygomatic bone, or the skull base. Such condition has dramatically negative effects on the patient's physical and mental health, causing a low quality of life (2).

TMJ ankylosis usually occurs before ten years of age but can be present at any age. It is commonly seen in patients within 20-30 years of age, and is more prevalent among males than females (1:2 vs. 1:4). The unilateral type has been reported to be more common than the bilateral type. Ankylosis of joint can be the true or false type. In the former case, the damage causes intra-articular connection of the condyle to the glenoid fossa, while in the latter type, the joint can become hypomobile due to extra-articular causes, such as: hyperplasia of the coronoid process, untreated fracture of the zygomatic arch, dental surgery, radiation fibrosis of the temporal muscle and neurological or psychological disorders (3).

Trauma has been recognized as the most common and important cause of TMJ ankylosis, and the severity of ankylosis is dependent upon the patient's age and the type of trauma (4, 5).

After trauma, local or systemic infections, for example: otitis media, mastoid inflammation, severe dental infections, tuberculosis, gonorrhoea and scarlet fever, are the second most frequent cause of ankylosis. Some systemic diseases such as ankylosing spondylitis, rheumatoid arthritis and psoriasis have

been reported as possible etiologic agents in less than 10% of cases (4-6).

There are several imaging techniques with varying degrees of success in the evaluation of a clinical condition to assess the changes in TMJ following a trauma, degenerative disorders or deformations (7, 8).

Conventional X-ray and tomography of TMJ have limited application since they may generate deformed or unsharp images, some with overlapping structures (9, 10).

Imaging techniques like MRI and ultrasound are specifically used for the assessment of the TML disk and soft tissue (11).

CT is another method for radiographic assessment of TMJ, which is superior to tomography in revealing minor changes on the TMJ surface. A CT image can display pathological changes such as osteophyte, condylar head erosion and fractures, ankylosis, dislocation and growth-developmental disorders. It has sensitivity and specificity rates of 70% and 100% respectively for the assessment of bone changes (12).

The development of CT and MRI (coronal CT in particular) has improved the assessment of the TMJ region by providing undisrupted images which delivered far better views than traditional films (13).

Recently, MRI has significantly aided the practice of TMJ radiography and has enabled imaging of ankylosis/fibrosis. However, CT is still superior to MRI in showing bone abnormalities. Since coronal CT is capable of fully determining the extent of abnormality, it has been readily adopted by surgeons. Coronal CT is exclusively useful for evaluating patients with ankylosis, and appears to be valuable in the workup before the treatment (9).

Although CT and MRI are gold standards in radiological detection of mandibular condyle fractures and ankylosis of temporomandibular joint, several factors have, in reality,

limited the routine use of CT for the mentioned purpose, such as: the high radiation dose in CT, inaccessibility in certain regions, high cost and thus being unaffordable for low-income patients (10, 14, 15).

Accurate radiology and clinical assessment could be of great help to the management of TMJ ankylosis. For instance, repositioning the musculofascial flap of the temporalis has proved successful in preventing reankylosis (16).

CBCT has recently become the imaging modality of choice for TMJ radiography and diagnosis of TMJ ankylosis (17-20).

CBCT can provide images of bony structures with a relatively high spatial resolution, while offering a reduced imaging dose compared to CT (21, 22).

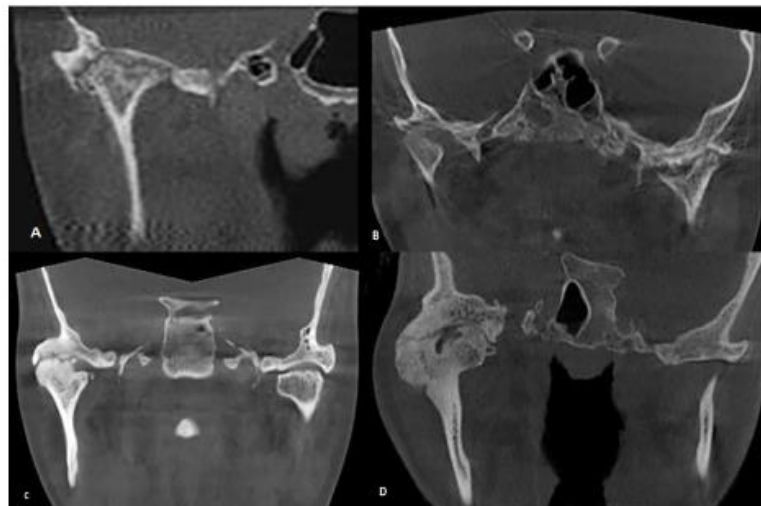
Therefore, the application of CBCT to assess the severity of TMJ ankylosis seems to be a promising approach (10). Since no study involving the use of CBCT in this field has been conducted in Iran, the current study was designed to evaluate the CBCT results of various types of temporomandibular joint ankylosis.

## Materials and Methods

A total of 32 ankylosed temporomandibular joints from 26 patients (12 males and 14 females) aged 8-65 years (mean age:  $29.8 \pm 14.3$ ) were included in this cross-sectional study. All of these patients had history of trauma and this problem had caused TMJ ankylosis. These patients had referred to a private maxillofacial clinic between 2013 and 2016 for CBCT imaging of TMJ, and the diagnosis of ankylosis had been established by a maxillofacial surgeon based on the clinical finding of the history of progressive difficulty in opening the mouth. CBCT was necessary for the diagnostic and therapeutic assessment of

these patients. All of the CBCT images had been obtained using a Planmeca Promax 3d device and operating in FOV  $90 \times 100$ , Voxel size  $200 \mu\text{m}$ , 88KVp, 8mAs, 12s. The software for processing the radiograph was Planmeca romexis 5.3.2. Based on the patients' clinical circumstances, some of the images had focused on the frontal plane of TMJ and others on the joint orientation. All images had been taken with the mouth closed and the maximum occlusion of the teeth. In this study, both the archived images of patients diagnosed with ankylosis (provided by a maxillofacial surgeon) and those of new patients (referred to radiology clinics by a maxillofacial surgeon for CBCT imaging) were used. New patients with obvious signs of TMJ ankylosis for whom the surgeon requested a CBCT image in order to complete their treatment process were selected. These patients had a history of progressive limited mouth opening or a long history of limited mouth opening.

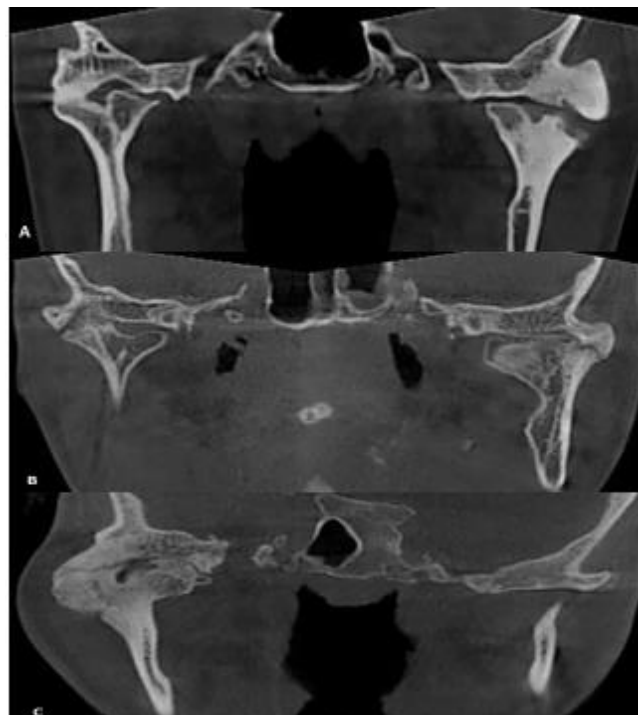
Sawhney's classification of the different types of TMJ ankylosis, which is a common classification, was used in the assessment of CBCT images. Based on this classification, there are four types of ankylosis. In type 1, the condyle head is flattened or deformed, but lies near the articular surface with dense fibrous connections. In type 2, the condyle head is flattened or deformed, but is still recognizable in close contact with the articular surface, representing a bony fusion. In type 3, a bony bridge passes between the mandible ramus and the zygomatic arch. The condyle head is displaced and atrophic, remaining connected to the median part of ramus. In type 4, there is a wide bony block between the ramus and the articular surface that has completely replaced the articular structure (23, Fig. 1).



**Figure 1.** Sawhney's classification: A) Type I, B) Type II, C) Type III, D) Type IV

For further evaluation and comparison, Dongmei's classification was used in addition to Sawhney's. According to this classification, TMJ ankylosis types are as follows: type A<sub>1</sub>, fibrous ankylosis without any bony fusion in the joint, type A<sub>2</sub>, ankylosis with bony connections in the lateral side of the joint,

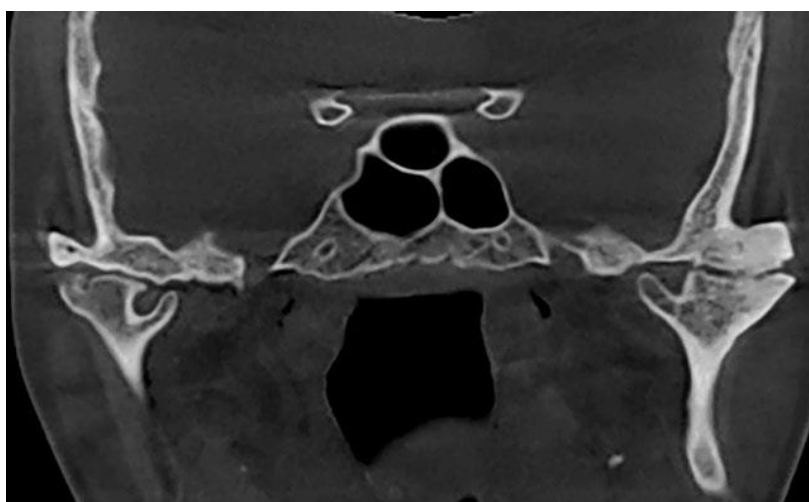
while the intact segment of the condyle is larger than half of the condyle head in the median section, type A<sub>3</sub>, similar to A<sub>2</sub> except that the intact condylar segment is smaller than half of the condyle head and type A<sub>4</sub>, ankylosis with complete bony connections around the joint (13, Fig. 2).



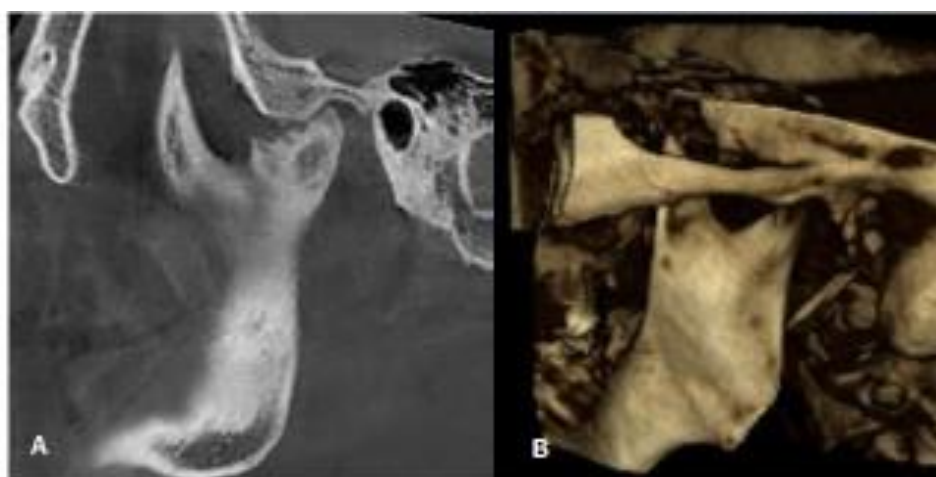
**Figure 2.** Dongmei's classification: A) Type II, B) Type III, C) Type IV

In this study, age and sex of the patients, history of trauma, ankylosis type based on both Sawhney's and Dongmei's classifications, growth of the condyle-glenoid fossa connection, medial displacement of the condyle head (Fig. 3), hypertrophic coronoid process, and extent of mouth opening, were all taken into account in the investigation. The extent of mouth opening was measured by positioning a graded caliper between the two incisal edges of the maxilla and mandible teeth (while the

patients were asked to open their mouth as much as possible), and was classified in four grades based on the mouth opening condition: A) does not open at all, B) opens less than 10 mm, C) opens 10 to 25 mm, D) opens more than 25 mm. The tip of the hyperplastic coronoid process extends at least one centimeter above the lower rim of the zygomatic arc (24, Fig. 4).



**Figure 3.** Medial displacement of condyle head



**Figure 4.** Hyperplastic coronoid process: A) Sagittal view, B) 3D view

The growth of the condyle-glenoid fossa connection was also divided into partial and total adherence. Partial connection was subdivided into lateral and medial forms (Fig. 5).

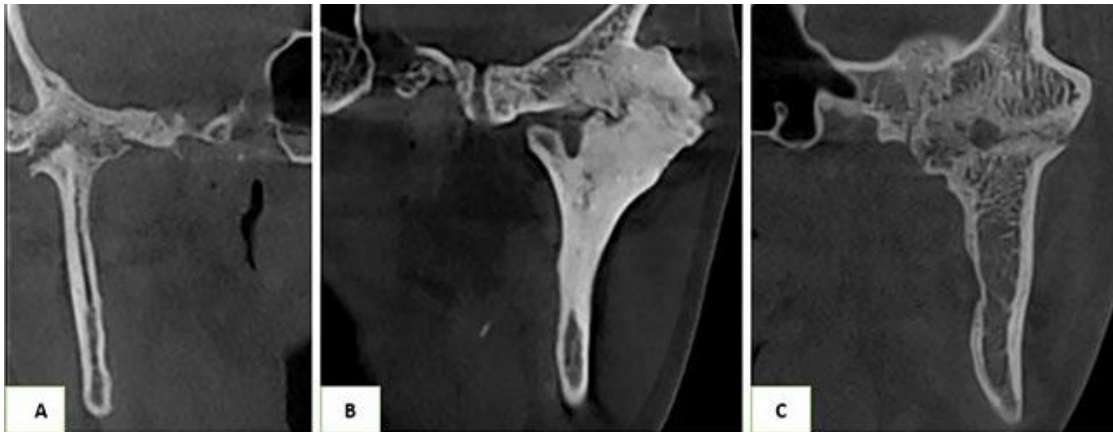


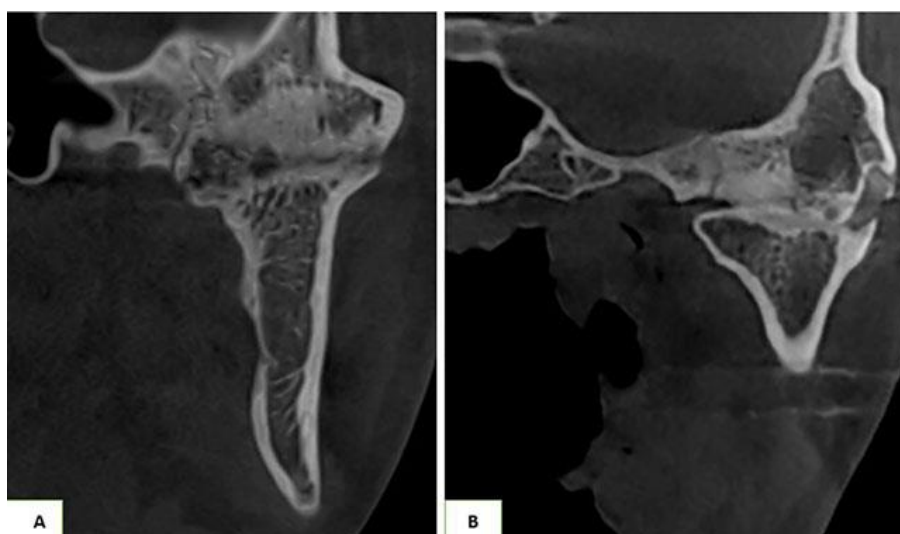
Figure 5. Type of condyle-glenoid fossa connection: A) Medial, B) Lateral, C) Total

A number of morphological parameters were defined as follows. Bony mass diameter (D1) was considered as the distance between the lateral and medial poles of the involved condyle (Fig. 6a). Width of the bony connection (D2) was the distance between one lateral condylar pole - in case that there was a connection from the lateral condylar head - and the most

prominent point at the bony fusion area towards the joint space (Fig. 6b). D3 denoted the degree of calcification in the bony fusion area, and was divided into two types: type 1) incomplete calcification with a radiolucent zone (presence of intact joint space), type 2) complete calcification without any radiolucent zones (Fig. 7). D4 was representative of the D2/D1 ratio (10).

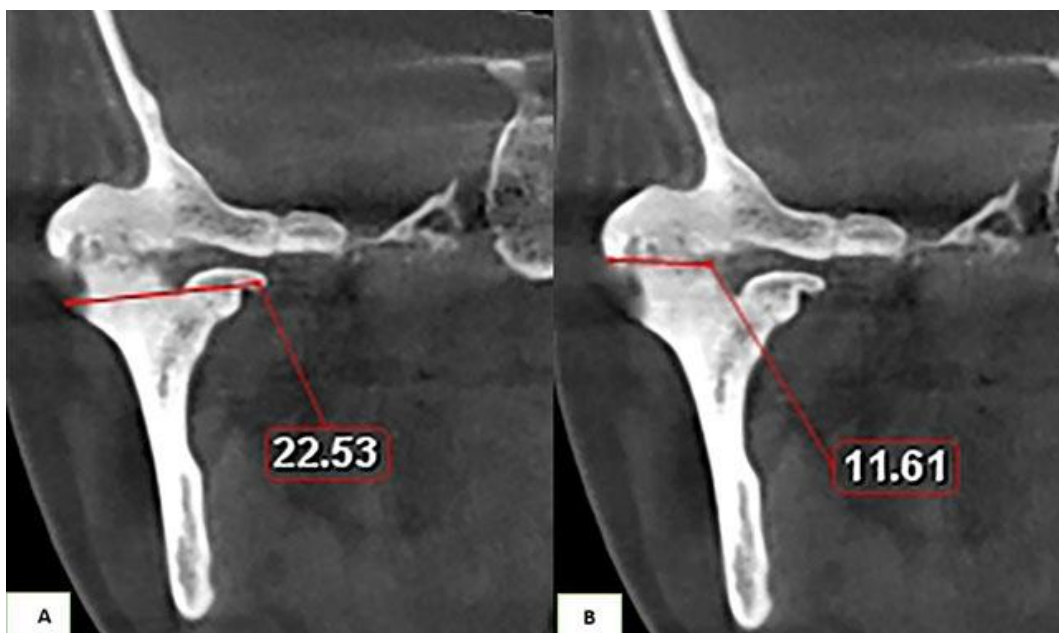

Figure 6. Morphological parameters: A) Bony mass diameter (D1); B) Width of the bony connection (D2)



**Figure 7.** Degree of calcification in bony fusion area (D3): A) Type 1, incomplete calcification with a radiolucent zone (presence of intact joint space); B) Type 2, complete calcification without any radiolucent zones

Sagittal images were oriented exactly perpendicular to the long axis of the condyle, and the coronal images parallel to this axis, with a distance of 1 mm between these slices. 1-mm slices spanned the entire joint area. To measure D1 and D2 variables, five middle slices were employed with a diameter that matched the maximum width of the bony fusion area in each joint. The measurement was calculated as the average of these five slices.

#### Statistical methods and sampling

In order to interpret the gathered data, SPSS software Ver. 2013 was utilized. Comparison of variables D1, D2, D3, and D4 for the condyles with and without protrusive or lateral condylar path was performed using an independent t-test. Kappa test was used to measure the agreement level between Sawhney's and Dongmei's classifications. Mann-Whitney test was employed to evaluate the frequency of classification of Sawhney's and Dongmei's variables in two groups which were defined based on the presence or absence of: choroid hyperplasia, condylar head displacement, osteophyte, erosion, and dysphagia. Mann-Whitney test was also used to evaluate

the frequency of distribution of Sawhney's and Dongmei's classification variables in regard to partial and total condylar connections. Kruskal-Wallis test was selected as the method for calculating the frequency of Sawhney's and Dongmei's classification variables with respect to the condylar location on the sagittal plane. In order to investigate the relationship between D1-4 variables and the extent of mouth opening as well as extrusive or lateral luxation, Spearman's correlations coefficient and ordinal regression were used. The statistical significance level was set at  $P=0.05$ . All tests revealed statistically meaningful results ( $P<0.05$ ).

#### Ethical considerations

In view of the fact that all patients with suspected ankylosis required CBCT imaging for the establishment of diagnosis, there was no ethical issue for consideration. The Ethical Approval Code issued for this study is IR.mums.sd.REC.1395.113.

## Results

This study included 26 patients; 12 males and 14 females, aged 8-65 with a mean age of  $29.8 \pm 14.3$  years. Four out of 12 men and 2 out of 14 women had two affected condyles. Thus, 32 condyles were assessed in total. In this study, 87.5% of the ankylosed condyles had a history of trauma.

Both Sawhney's and Dongmei's classification variables showed a slightly positive correlation with age. In other words, each of these variables increased with an increase in age; that is, more serious forms of ankylosis were more common in older ages and vice versa. The intensity of the relationship, however, was not significant ( $P > 0.05$ ).

All four variables of D1, D2, D3 and D4 were negatively correlated with the extent of mouth opening, but the correlation was not significant ( $P > 0.05$ ). This means that with an increase in the extent of mouth opening, the value of each of these four variables decreased and vice versa. The average of the mentioned four variables was lower in condyles with protrusive and lateral movement but the difference was not significant ( $P > 0.05$ ).

According to Sawhney's classification, the frequency value of types I, II, III and IV were 3, 16, 10 and 3 respectively, while based on Dongmei's classification, the frequency value of grades I, II, III and IV were 1, 15, 14 and 2 respectively. The level of agreement between the two modes of classification was significantly low ( $P = 0.003$ ).

The frequency value of the group with medial condylar displacement was higher than that of the group without condylar head displacement in all types of the Sawhney's grading. Overall, the average value of Sawhney's classification variables was greater in the group with condylar head displacement relative to the group without condylar head

displacement, but this difference was not statistically significant ( $P > 0.05$ ). The highest degree of condylar head displacement was observed in Sawhney's types II and III. The average value of Dongmei's classification variables was significantly higher in the group with condylar head displacement compared to the group where this was not observed ( $P = 0.028$ ). The highest degree of condylar head displacement was seen in Dongmei's type III.

Lateral condylar connection (19 cases, 59.4%), medial condylar connection (9 cases, 28.1%) and total adherence of the condylar head (4 cases, 12.5%) were the most frequent connections of condylar head, respectively. Accordingly, the lateral connection in Sawhney's type III displayed the highest frequency among these three connection types within this classification method. Overall, there was no significant correlation between the three types of condylar head connection ( $P > 0.05$ ).

Based on Dongmei's classification, there was a significant difference between the three types of condylar head connection. In pairwise comparison of these connection types, a significant correlation was only observed between the medial and the total adherence types ( $P < 0.05$ ). In this sense, the lateral connection in Dongmei's type III exhibited the highest frequency among the three different connection types within this classification approach. In more severe grades of Sawhney's and Dongmei's classifications, most condylar head and glenoid fossa connections existed in the lateral side of the joint.

The average values of Sawhney's and Dongmei's classification variables were higher in the group with coronoid hyperplasia than in the group in which it was absent, but the difference was not significant ( $P > 0.05$ ). The highest degree of coronoid hyperplasia was seen in Sawhney's type II grade.



According to Dongmei's classification, the highest degree of coronoid hyperplasia was related to types II and III.

## Discussion

Ankylosis of temporomandibular joint is a debilitating condition and often adversely affects the quality of life of patients. It commonly affects mastication, digestive system, speaking, individual appearance and oral health of the patients (14, 25-27).

In this study, two methods of Sawhney and Dongmei classifications were used to classify the condyles affected with ankylosis. Dongmei classification gives this idea to the surgeon that it is not necessary to resect the intact condyle fragment that has been medially displaced and it is large enough to withstand the force (13).

In this study, 32 condyles from 26 patients with an age range of 8-65 years (mean age of  $29 \pm 14.3$ ) were investigated. In whole, 28 out of 32 condyles had a history of trauma in the past. Five patients with unilateral involvement of the joints were younger than 11 years, while in Malik *et al.* study, there was no case of ankylosis aged less than 11 years and they have claimed that the facial bone fractures are relatively uncommon in children, which is probably due to the elasticity of bones in them (28). Dahlstrom *et al.* stated that although complications due to trauma are less frequent in children than in adults, children under 11 years are also susceptible to TMJ ankylosis (29). Other studies have also noted that TMJ ankylosis usually begins before ten years of age but can be detected in any age. They concluded that the patient's age at the time of injury is considered as an important factor in assessing maxillofacial deformities in TMJ ankylosis. Injury during childhood causes imperfect osteogenesis of cartilage in ankylosis process and

along with the absence of muscular guidance during the process of mandibular growth, results in extensive maxillofacial changes in patients, including unilateral intra-capsular ankylosis (3, 30, 31).

Trauma was recognized as the most common cause of ankylosis in our study (28 of 32 condyles, 87.5%), which was in agreement with several previous studies (2-6, 10, 13, 14, 30, 32-35). Aggarwal and his colleagues reported that a joint more affected with trauma (which is morphologically disrupted) is expected to show a more severe type of ankylosis (9). In a study on 70 patients, Sawhney attributed larger bony mass of ankylosis to more severe traumas (23).

In Ferretti *et al.* study, the risk of ankylosis was 13.3 times higher in joints with medial condylar displacement than that in other types of condylar fractures. They also stated that even if the risk of ankylosis in joints having fracture with medial condylar displacement be equal with other types of condylar fractures, due to a higher incidence of the former type of fracture compared to other fractures, there will be a higher number of ankyloses as a result of this type of damage (33). In Ferretti's study, 75% of the condyles affected with ankylosis that had a history of trauma had been medially displaced, which was more frequent in Sawhney's types II and III cases. Furthermore, the average Dongmei's classification variable was significantly higher in the group with medial condylar head displacement compared to the groups lacking it ( $p=0.028$ ). According to Dongmei's classification (in the coronal plane), bony connection occurs in lateral direction of the joint and the remaining part of the joint in medial direction is an important factor in determining the type of ankylosis. Thus, medial displacement of the injured condyle can be assessed.

According to Ferretti and his colleagues, an increased risk of ankylosis after medial displacement of a fractured condyle is due to the following reasons. Firstly, elimination of condyle as a vertical support enables a closer fracture surface to the base of the skull, which increases the likelihood of trans-articular bone fusion. Secondly, condylar head displacement creates a cavity that is quickly filled with blood and leads to hematoma. The hematoma disrupts the periosteal covering and the joint capsule secretes beyond the old site of condylar head. They also stated that condylar fractures with medial displacement in a patient having bilateral condylar fracture can be a major risk factor for ankylosis due to the lack of movement (33).

In 1982, Rowe reported that ankylosis can be a result of sagittal fracture of the condyle (36). In addition, Duan and colleagues have reported that type III sagittal condylar fractures are associated with disk displacement, which is a high-risk condition for TMJ ankylosis (37). Animal studies also have showed that sagittal condylar fractures can lead to severe TMJ injury and the changes can subsequently progress to TMJ ankylosis (38). The results of Deng *et al.* study suggested that the lateral pterygoid muscle mimics distraction osteogenesis effects during the repair process of sagittal condylar fracture, which is an important factor in the pathogenesis of bony TMJ ankylosis during the repair process (2). Dongmei *et al.* in their study found a strong relationship between splitting fractures of sagittal condyle with simultaneous mandibular fractures in pathogenesis description of TMJ ankylosis. Sagittal fracture mandibular condyle (SFMC) is a vertical fracture involving condylar head and capsule. They suggested that the combination of this intra-capsular fracture with widening of mandible results in

lateral or lateral-superior displacement of lateral condylar pole (stump) relative to zygomatic arch, its direct contact with arch bone and fusion with the arc. This type of ankylosis is known as juxta-articular ankylosis, which occurs lateral to the articulation itself. Their justification for fusion to zygomatic arc was that the broken fragment is sagittal of cancellous bone, which is deformed and fused to the arc (39). According to the studies of Arakeri *et al.*, Anyanechi and Xiang *et al.*, condylar fractures are often associated with concomitant fractures in other regions of mandible that leads to an increase in the size (widening) of mandible arc and is related to the development of TMJ ankylosis (4, 14, 40). According to Anyanechi, the main factors associated with the development of TM ankylosis include lower age, long interval between injury and treatment of condylar fractures and simultaneous fractures of mandible and midface (14).

In the present study, the effect of four variables (D1 to D4) on the extent of mouth opening were examined. Although none of these variables had a significant relationship with the extent of mouth opening, they showed a negative correlation with the extent of mouth opening. In other words, decreased value of each of these variables (if other variables were constant) caused a lower extent of mouth opening. According to D3 variable, the chance of opening the mouth was lower in the group lacking joint space (type II) relative to the group having this space (type I). In the study of Yan and colleagues, all the D variables (except for D1) had a negative correlation with the extent of mouth opening. In their study, D2 and D3 were independent factors that had an impact on opening the mouth and the effect of D3 variable on opening the mouth was even more than D2.

They hypothesized that a radiolucent region in bone fusion area may indicate the degree of calcification in this area, which will be one of the factors influencing the mouth opening. Their results also indicated that the remaining degree of mouth opening in patients with complete bony ankylosis is probably not a function of mandible elasticity or movement in cranial sutures, but due to inadequate calcification in the bone fusion area that cannot completely limit the movement of ankylosis joint. Measurement of bone density in the area of bone fusion in terms of Hounsfield number may be a good approach to measure the degree of calcification. However, calculating this CT value is really difficult because bone fusion area is not homogeneous and there is a tiny radiolucent space (10). In the study of Zhang and colleagues, a small number of patients with type III and IV ankylosis based on Sawhney's classification were able to open their mouth to a higher extent, which demonstrates that the expansion of bone fusion area is not the only factor affecting mouth opening (41). In addition, in the present study, the influence of four D variables on protrusive and lateral movement was also examined. The average value of all the four variables (D1, D2, D3 and D4) was lower in condyles with protrusive and lateral movement than those without these movements but this difference was not significant ( $P>0.05$ ).

In our study, D3 value was equal to 1 in 90.6% of cases, indicating that the bone mass formed in the joint ankylosis region is not homogeneous and has a radiolucent zone. In the study of Yan and colleagues, the bone mass in ankylosis area was not homogeneous in 29 out of 38 condyles (76.3%) and they stated that the radiolucent zone may be indicative of the degree of calcification in bone fusion area and it will therefore be one of the factors influencing the opening of mouth (10).

Analysis of CT features of bone ankylosis by Aggarwal and colleagues showed that the injury was not just a simple bone mass (which seemed to be plain in the images), but it was a bone mass consisting of two bony blocks separated by a radiolucent zone in most patients. In their study, they observed a radiolucent, irregular and transverse zone in a new bone, namely 49 out of 64 joints affected with ankylosis, which was more common in type II Aggarwal ankylosis (9). In our study, this radiolucent zone was more extensive in type II of both Dongmei's and Sawhney's classifications, too. Aggarwal and colleagues reported that this radiolucent zone is not indicative of a real fracture since there was no mobility or movement between the two bone masses. They also believed that this area does not show an independent joint space since no specific rupture plan was observed in the new bone mass during surgery. Aggarwal and colleagues called this radiolucent zone pseudo-fracture and believed that it probably shows a dense fibrous band between two new bone masses. The width of the pseudo-fracture zone ranged from an obvious gap to a hairline that was only visible in the bone window (9). Ferretti and his colleagues also repeatedly detected remains of fibrocartilage tissue in many TMJs afflicted with ankyloses (33), which was proven by other reports (23). All the ankylosed joints in the study of Ferretti showed a partial joint space that was probably caused by a disc within the ossified area (33). Based on the assumption of Pirok and colleagues, if ankylosis was only a simple organization along with the ossification of an intra-capsular hematoma, it should have been similar to normal healing of fractures, while the ankylosis progressed during a much longer period with a radiolucent zone between bone fusion areas (42).

In the present study, bone connection was formed in lateral side of the joint in the majority of patients (59.4%). Meanwhile, from 19 condyles with bony connection on lateral side of the joint, 16 cases had also medial condylar movement. In other words, two-third of the condyles with medial displacement were fused in the lateral side of the joint to the temporal bone. Qiu *et al.* found that in a number of patients with TMJ ankylosis after trauma, bone fusion was only present in the lateral side of TMJ, while the intact condylar head was medially displaced (43). In the study of Li and colleagues, the bony connection of lateral part of fossa with condyle was confirmed, but the space between cranial base and the remaining condyle was intact (44). Medial displacement of the fractured condylar head creates a cavity through the stretch of lateral pterygoid muscle that is quickly filled with blood and produces a large hematoma, which is subsequently ossified and is an important factor in the formation of a bony bridge in lateral joint side in TMJ ankylosis (2, 33, 45).

In this study, 65.5% of condyles affected with ankylosis showed coronoid hyperplasia. Approximately 57% of the ankylosed condyles with hyperplasia were in class B in terms of mouth opening and opened their mouth less than 10 mm. Previous studies have suggested that hyperplastic coronoid process causes limited mouth opening (3, 46, 47). In our study, over half of the ankylosed joints with hyperplastic coronoid had difficulty opening their mouth and could not open it more than 10 mm. Wang and colleagues have reported more extensive coronoid hyperplasia in older TMJ ankylosis with more restrictions in opening the mouth. They also

reported that a hyperplastic coronoid process could lead to restrictions in opening the mouth because of fibrosis in temporalis muscles as well as interference between the long coronoid process and the zygomatic arc. In fact, hyperplasia of coronoid process, itself, can cause restricted opening of the mouth without TMJ ankylosis even in patients without any interference between coronoid process and zygomatic bone (47). Isometric contractions of mastication system muscles may occur if the joint ankylosis lasts for a longer period, which can be a reason for elongation and thickening of coronoid process (temporalis muscle). In general, increased duration of TMJ ankylosis can increase the incidence of elongated coronoid process. In the study of Kumar and colleagues, the ankylosis period was associated with an increased incidence of coronoid process elongation (48).

Xia *et al.* have reported in their study on 71 patients that there is an association between the clinical features and types of temporomandibular joint ankylosis. They also found that younger trauma patients with long post-trauma periods tended to develop more severe TMJ ankylosis, experience more complications, and face more challenges in the course of treatment compared with older patients (49). Conversely, in the present study, severe cases of ankylosis were seen among older patients, which may not be a significant difference between the findings of the two studies.

## Conclusions

CBCT seems to have become the most advantageous modality of imaging with reference to TMJ abnormalities, including ankylosis. Although the application of the two

common classifications (Sawhney's and Dongmei's) produced a low level of agreement in terms of radiological findings, it appears that the employment of such classifications in conjunction with CBCT imaging is a promising approach for the diagnosis and evaluation of TMJ ankylosis. Such statement sounds even more reasonable when considering a number of comparative benefits that CBCT imaging tends to provide, such as: no image overlap or distortion, refined radiation dose, pixel enhancement and the ability to display hard tissues.

## References

1. Alomar X, Medrano J, Cabratosa J, Clavero JA, Lorente M, Serra I, et al. Anatomy of the temporomandibular joint. *Semin Ultrasound CT MR* 2007; 28(3):170-83.
2. Deng TG, Liu CK, Liu P, Zhang LL, Wu LG, Zhou HZ, et al. Influence of the lateral pterygoid muscle on traumatic temporomandibular joint bony ankylosis. *BMC Oral Health* 2016; 16(1):62.
3. Bello SA, Aluko Olokun B, Olaitan AA, Ajike SO. Aetiology and presentation of ankylosis of the temporomandibular joint: report of 23 cases from Abuja, Nigeria. *Br J Oral Maxillofac Surg* 2012; 50(1):80-4.
4. Arakeri G, Kusanale A, Zaki GA, Brennan PA. Pathogenesis of post-traumatic ankylosis of the temporomandibular joint: a critical review. *Br J Oral Maxillofac Surg* 2012; 50(1):8-12.
5. Kumar LK, Manuel S, Kurien NM, Khalam SA, Menon VP. An interesting radiological picture of post traumatic TMJ ankylosis due to sagittal condylar fracture. *Int J Surg Case Rep* 2015; 12:11-4.
6. Ko EW, Huang CS, Chen YR, Figueroa AA. Cephalometric craniofacial characteristics in patients with temporomandibular joint ankylosis. *Chang Gung Med J* 2005; 28(7):456-66.
7. Ahmad M, Hollender L, Anderson Q, Kartha K, Ohrbach R, Truelove EL, et al. Research diagnostic criteria for temporomandibular disorders (RDC/TMD): development of image analysis criteria and examiner reliability for image analysis. *Oral Surg Oral Med Oral Pathol Oral Radiol Endod* 2009; 107(6):844-60.
8. Crow H, Parks E, Campbell JH, Stucki DS, Daggy J. The utility of panoramic radiography in temporomandibular joint assessment. *Dentomaxillofac Radiol* 2014; 34(2):91-5.
9. Aggrawal S, Mulhopadhyay S, Berry M, Bhargava S. Bony ankylosis of the temporomandibular joint: a computed tomography study. *Oral surgery, oral medicine, oral pathology* 1990;69(1):128-32
10. Yan Y, Zhang Y, Sun Z, Li J, Xiao E, An J. The relationship between mouth opening and computerized tomographic features of posttraumatic bony ankylosis of the temporomandibular joint. *Oral Surg Oral Med Oral Pathol Oral Radiol Endod* 2011; 111(3):354-61.

## Acknowledgements

This study was made possible with the generous support rendered by the Vice Chancellor for Research of Mashhad University of Medical Sciences in the form of a grant (No. 941569), for which the authors are very grateful.

## Conflict of Interest Statement

None

11. Roh HS, Kim W, Kim YK, Lee JY. Relationships between disk displacement, joint effusion, and degenerative changes of the TMJ in TMD patients based on MRI findings. *J Craniomaxillofac Surg* 2012; 40(3):283-6.
12. Alkhader M, Kuribayashi A, Ohbayashi N, Nakamura S, Kurabayashi T. Usefulness of cone beam computed tomography in temporomandibular joints with soft tissue pathology. *Dentomaxillofac Radiol* 2010; 39(6):343-8.
13. He D, Yang C, Chen M, Zhang X, Qiu Y, Yang X, et al. Traumatic temporomandibular joint ankylosis: our classification and treatment experience. *J Oral Maxillofac Surg* 2011; 69(6):1600-7.
14. Anyanechi CE. Temporomandibular joint ankylosis caused by condylar fractures: a retrospective analysis of cases at an urban teaching hospital in Nigeria. *Int J Oral Maxillofac Surg* 2015; 44(8):1027-33.
15. Shintaku WH, Venturin JS, Azevedo B, Noujeim M. Applications of cone-beam computed tomography in fractures of the maxillofacial complex. *Dent Traumatol* 2009; 25(4):358-66.
16. Katsnelson A, Markiewicz MR, Keith DA, Dodson TB. Operative management of temporomandibular joint ankylosis: a systematic review and meta-analysis. *J Oral Maxillofac Surg* 2012; 70(3):531-6.
17. Hintze H, Wiese M, Wenzel A. Cone beam CT and conventional tomography for the detection of morphological temporomandibular joint changes. *Dentomaxillofac Radiol* 2007; 36(4):192-7.
18. Honda K, Larheim TA, Maruhashi K, Matsumoto K, Iwai K. Osseous abnormalities of the mandibular condyle: diagnostic reliability of cone beam computed tomography compared with helical computed tomography based on an autopsy material. *Dentomaxillofac Radiol* 2006; 35(3):152-7.
19. Honey OB, Scarfe WC, Hilgers MJ, Klueber K, Silveira AM, Haskell BS, et al. Accuracy of cone-beam computed tomography imaging of the temporomandibular joint: comparisons with panoramic radiology and linear tomography. *Am J Orthod Dentofacial Orthop* 2007; 132(4):429-38.
20. Tsiklakis K. Cone beam computed tomographic findings in temporomandibular joint disorders. *Alpha Omegan* 2010; 103(2):68-78.
21. Ludlow JB, Ivanovic M. Comparative dosimetry of dental CBCT devices and 64-slice CT for oral and maxillofacial radiology. *Oral Surg Oral Med Oral Pathol Oral Radiol Endod* 2008; 106(1):106-14.
22. Schulze D, Heiland M, Thurmann H, Adam G. Radiation exposure during midfacial imaging using 4- and 16-slice computed tomography, cone beam computed tomography systems and conventional radiography. *Dentomaxillofac Radiol* 2004; 33(2):83-6.
23. Sawhney CP. Bony ankylosis of the temporomandibular joint: follow-up of 70 patients treated with arthroplasty and acrylic spacer interposition. *Plast Reconstr Surg* 1986; 77(1):29-40.
24. White SC, Pharoah MJ. *Oral Radiology: Principles and Interpretation*. 7th ed. Amsterdam: Elsevier, Health Sciences Division; 2014.
25. Andersson J, Hallmer F, Eriksson L. Unilateral mandibular condylar fractures: a 31-year follow-up of non-surgical treatment. *Int J Oral Maxillofac Surg* 2007; 36(4):310-4.
26. Remi M, Christine MC, Gael P, Soizick P, Joseph-Andre J. Mandibular fractures in children: long term results. *Int J Pediatr Otorhinolaryngol* 2003; 67(1):25-30.

27. Rutges JP, Kruizinga EH, Rosenberg A, Koole R. Functional results after conservative treatment of fractures of the mandibular condyle. *Br J Oral Maxillofac Surg* 2007; 45(1):30-4.
28. Malik NA. *Textbook of Oral and Maxillofacial Surgery*. 3rd ed. New Delhi: Jaypee Brothers Medical Pub; 2012.
29. Dahlstorm L, Kahnberg KE, Lindahl L. 15years follow-up on condylar fractures. *Int J Oral Maxillofac Surg* 1989;18(1):18-23.
30. Nam SM, Kim YB, Lee SJ, Park ES, Lee JH. A comparative study of intraoral versus retromandibular approach in the management of subcondylar fracture. *BMC Surgery* 2019; 19(1):28.
31. Vasconcelos BC, Bessa-Nogueira RV, Cypriano RV. Treatment of temporomandibular joint ankylosis by gap arthroplasty. *Med Oral Patol Oral Cir Bucal* 2006; 11(1):66-9.
32. El-Hakim IE, Metwalli SA. Imaging of temporomandibular joint ankylosis. A new radiographic classification. *Dentomaxillofac Radiol* 2002; 31(1):19-23.
33. Ferretti C, Bryant R, Becker P, Lawrence C. Temporomandibular joint morphology following post-traumatic ankylosis in 26 patients. *Int J Oral Maxillofac Surg* 2005; 34(4):376-81.
34. Long X, Goss AN. Pathological changes after the surgical creation of a vertical intracapsular condylar fracture. *Int J Oral Maxillofac Surg* 2007; 36(9):834-7.
35. Meng FW, Zhao JL, Hu KJ, Liu YP. A new hypothesis of mechanisms of traumatic ankylosis of temporomandibular joint. *Med Hypotheses* 2009; 73(1):92-3.
36. Rowe NL. Ankylosis of the temporomandibular joint. *Journal of the Royal College of Surgeons of Edinburgh*. 1982;27(2):67-79.
37. Duan D, Zhang Y. A clinical investigation on disc displacement in sagittal fracture of the mandibular condyle and its association with TMJ ankylosis development. *International journal of oral and maxillofacial surgery*. 2011; 40(2):134-8.
38. Long X, Goss AN. A sheep model of intracapsular condylar fracture. *Journal of Oral and Maxillofacial Surgery* 2007; 65(6):1102-8.
39. Dongmei He, Ellis 3rd E, Zhang Y. Etiology of temporomandibular joint ankylosis secondary to condylar fractures: the role of concomitant mandibular fractures. *J Oral Maxillofac Surg* 2008; 66(1):77-84.
40. Xiang GL, Long X, Deng MH, Han QC, Meng QG, Li B. A retrospective study of temporomandibular joint ankylosis secondary to surgical treatment of mandibular condylar fractures. *Br J Oral Maxillofac Surg*. 2014; 52(3):270-4.
41. ahlstorm L, Kahnberg KE, Lindahl L. 15years follow-up on condylar fractures. *Int J Oral Maxillofac Surg* 1989;18(1):18-23.
42. Zhang Y, He DM, Ma XC. [Posttraumatic temporomandibular joint ankylosis: clinical development and surgical management]. *Zhonghua Kou Qiang Yi Xue Za Zhi* 2006; 41(12):751-4. [In Chinese].
43. Pirok Dj, Merrik RG. Dislocation of the mandibular condyle into the middle cranial fossa. Report of a case. *Oral surgery, oral medicine and oral pathology*. 1970;29(1):13-8.
44. Qiu YT, Yang C, Wang YI, chen MJ, Zhang SY. Diagnosis and surgical treatment of temporomandibular joint ankylosis resulting from intracapsular conyle fracture. *China Journal of Oral and Maxillofacial Surgery* 2006;2:003.

44. Arya V, Chigurupati R. Treatment algorithm for intracranial intrusion injuries of the mandibular condyle. *J Oral Maxillofac Surg* 2016; 74(3):569-81.
45. Liu CK, Liu P, Meng FW, Deng BL, Xue Y, Mao TQ, et al. The role of the lateral pterygoid muscle in the sagittal fracture of mandibular condyle (SFMC) healing process. *Br J Oral Maxillofac Surg* 2012; 50(4):356-60.
46. Tavassol F, Spalthoff S, Essig H, Brecht M, Gellrich NC, Kokemuller H. Elongated coronoid process: CT-based quantitative analysis of the coronoid process and review of literature. *Int J Oral Maxillofac Surg* 2012; 41(3):331-8.
47. Wang WH, Xu B, Zhang BJ, Lou HQ. Temporomandibular joint ankylosis contributing to coronoid process hyperplasia. *Int J Oral Maxillofac Surg* 2016; 45(10):1229-33.
48. Kumar P, Singh V, Agrawal A, Bhagol A, Bali R. Incremental increase in percentage mouth opening after coronoidectomy in temporomandibular joint ankylosis. *Int J Oral Maxillofac Surg* 2015; 44(7):859-63.
49. Xia L, An J, He Y, Xiao E, Chen S, Yan Y, et al. Association between the clinical features of and types of temporomandibular joint ankylosis based on a modified classification system. *Sci Rep* 2019; 9(1):10493.